

# Clinical Localization of the Spasmodic Segment in Voice Limiting Pharyngoesophageal Spasm

<sup>1</sup>Mandar Deshpande, <sup>2</sup>Vishal Rao, <sup>1</sup>Pankaj Chaturvedi, <sup>1</sup>Devendra Chaukar

<sup>1</sup>Prathamesh Pai, <sup>3</sup>Anil K D'cruz

<sup>1</sup>Associate Professor and Assistant Surgeon, Department of Head and Neck Surgery, Tata Memorial Hospital, Dr Ernest Borges Road, Parel, Mumbai, Maharashtra, India

<sup>2</sup>Research Fellow, Department of Head and Neck Surgery, Tata Memorial Hospital, Dr Ernest Borges Road, Parel, Mumbai Maharashtra, India

<sup>3</sup>Professor and Chief, Department of Head and Neck Surgery, Tata Memorial Hospital, Dr Ernest Borges Road, Parel, Mumbai Maharashtra, India

**Correspondence:** Vishal Rao, Research Fellow, Department of Head and Neck Surgery, Tata Memorial Hospital, Dr Ernest Borges Road, Parel, Mumbai-400012, Maharashtra, India, Phone: 00-91-22-24177000, Ext. 7287, Fax: 00-91-22-24154005 e-mail: drvishalrao@yahoo.com

## Abstract

**Background:** Primary tracheoesophageal prosthetic speech is the gold standard for speech rehabilitation in patients undergoing total laryngectomy. However, despite a high success rate, the speech outcome can be suboptimal in 5-15% of these patients. The most frequent cause being hypertonicity of the pharyngoesophageal segment. We elaborate a simple clinical technique that can be performed in an outpatient clinic to identify the hypertonic pharyngoesophageal segment in patients with PES.

**Methods:** All these patients (13 males and 1 female) had undergone total laryngectomy and primary tracheoesophageal puncture followed by postoperative radiotherapy. Even after rigorous speech therapy, these patients had failed to develop fluent speech. The mean duration following surgery was 8 months (range 4-20 months). A simple clinical technique is elaborated utilizing the dermal ballooning effect observed in the cervical region to ascertain the site of pharyngo esophageal spasmodic segment.

**Results:** Using this technique we have been able to identify the hypertonic segment successfully in 13 of the 14 patients with PES. In these patients the trial lignocaine block was injected specifically at these points medial to the carotid vessels. Improvement in speech following the block was observed, and was further confirming using a videofluoroscopy.

**Conclusion:** This technique serves as a simple and useful clinical tool to map the spasmodic segment and to guide the injection site for trial lignocaine block and as well for botulinum a toxin. In addition, it also prevents inadvertent injection to the normal segments.

**Keywords:** Laryngectomy, Spasm, Alaryngeal speech.

## BACKGROUND

Laryngeal cancers form the second most common site for cancers in the upper aerodigestive tract. In the present era of organ preservation for the larynx, there still exists a select group of patients with advanced laryngeal cancers who continue to undergo a total laryngectomy in the course of their management.<sup>1</sup> It is a well-conceded fact that Tracheoesophageal Puncture (TEP) speech forms the most successful form of alaryngeal speech, and hence the method of choice for surgical voice rehabilitation following laryngectomy. However, despite various advances in speech rehabilitation prosthesis and surgical techniques, TEP related voice problems continue to persist.

Pharyngoesophageal segment comprises of the reconstructed remnant pharynx and the adjacent

cricopharynx. Pharyngoesophageal spasm (PES), which is the spasm of this segment, continues to be one of the most common causes for speech failure in patients following total laryngectomy with TEP. The key measures advocated in primary prevention include performing a cricopharyngeal myotomy or a unilateral pharyngeal neurectomy or both, to reduce the hypertonicity of PE segment. Despite adequate measures, the incidence of voice limiting PES ranges from 10-40% in literature.<sup>2</sup>

Various surgical and nonsurgical techniques, such as secondary cricopharyngeal myotomy or neurectomy, dilatation have been advocated to address this hurdle. The basic rationale being that these measures permit adequate airflow through the vibrating pharyngeal segment that permits fluent speech production. Over the recent years,

Chemical denervation of the PE segment with botulinium A toxin injection to improve TEP speech in patients with cricopharyngeal spasm has emerged as a promising tool in this regard.<sup>3-5</sup> It has opened a safe and reliable nonsurgical alternative technique for many patients who would otherwise have to be exposed to a much higher risk of surgical intervention. Especially in the present organ preservation era, when total laryngectomy is mainly reserved for locally advanced tumors, majority of them require postoperative radiotherapy, or in salvage setting postradiotherapy.

Accurate detection and localization of the hypertonic segment is a critical step in the success of this procedure. Video fluoroscopy still continues to be the most commonly used guide to mapping the spasmodic pharyngoesophageal segment and constitutes the current gold standard for radiological assessment of the spasmodic segment. However, it has been shown that the surface markings to map the spasmodic segment using this technique may not be precise, as the surface markings done may not exactly correspond to spasmodic segment, due to changes position of the patient during injection.<sup>6</sup> We elaborate a simple technique to identify the hypertonic pharyngoesophageal segment in patients with PES. This technique serves as a useful guide to map the injection site for trial lignocaine block and as well for botulinium A toxin. In addition, it also prevents inadvertent injection to the normal segments.

## MATERIALS AND METHODS

A retrospective review was made of 16 patients between 2006 and 2008 who underwent Botox injections (Allergan Pharmaceuticals, Ireland, Ltd.) as the initial treatment for pharyngeal constrictor muscle spasm after laryngectomy.

The mean age of these patients with pharyngoesophageal spasm (13 males and 1 female) was 61 years (Range 45-78). All these 14 patients with PES had undergone total laryngectomy with or without partial pharyngectomy and primary tracheoesophageal puncture followed by postoperative radiotherapy. All above patients did not receive any form of prior treatment for the disease. All patients presented with T4 disease with gross exolaryngeal spread and hence offered surgery as the primary treatment modality. Hypopharynx (Pyriform sinus) was the commonest subsite (9/14) and laryngeal cancers (supraglottic/glottis) comprising of 5 patients. Pharyngeal mucosal closure was performed 2 layered extramucosal or full thickness closure as per individual surgeons preference.

All patients except 1 underwent either neurectomy (7 patients) or myotomy (6 patients) intraoperatively as a prophylactic measure to prevent pharyngoesophageal spasm.

All the above patients had undergone rigorous speech rehabilitation following surgery, and had failed to develop fluent speech. The mean duration following completion of treatment was 8 months (range 4-20 months). Fiberoptic endoscopy and barium study had ruled out any anatomical or structural abnormality. Videofluoroscopy confirmed presence of hypertonic PES in all patients.

## TECHNIQUE

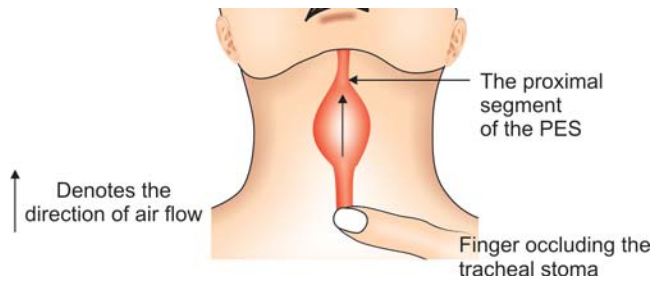
The patient with the PES is asked to phonate by occluding the stoma site with his finger and air column in the PE segment from the crown of the tracheostoma is traced upwards to its point of disappearance. This point at which the air column disappears marks the commencement of the proximal end (lower end of the PES) of the spasmodic segment (Figs 1 and 2).

The proximal site of the spasmodic segment, which corresponds to the point of disappearance of the air column can be reconfirmed on videofluoroscopy (Fig. 3). This ascending air column is clearly visible in the anterior cervical skin superior to the tracheostoma, medial to the carotids. The presence of PES was confirmed by using a trial lignocaine block. Lignocaine block is given using 6 ml of 2% solution of lignocaine in a 22/24G syringe and injected medial to the carotids at 3 points (2 ml each) along the length of the neopharynx, from the base tongue to the area just lateral to the crown of the tracheostoma.<sup>6</sup> Following the block, air column was observed rising above the previously marked point, thus reconfirming the proximal end of the spasmodic segment. This was associated with a perceptible improvement in speech in these patients. The distal segment (upper end of the PES) of the PES usually coincides with the junction of middle constrictors and base of tongue, which is confirmed using a video fluoroscopy.

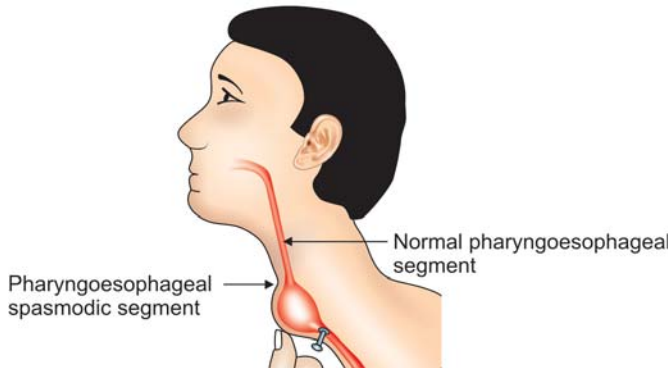
In a total laryngectomy patient with a normal pharyngoesophageal segment, the air column may be seen reaching the upper end of neck, which marks the junction of the base of tongue with the constrictors (Fig. 4).

## RESULTS

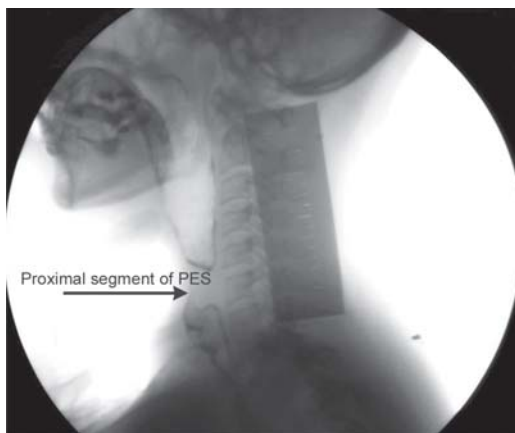Using this technique, we have been able to identify the hypertonic segment successfully in 13 of the 14 patients



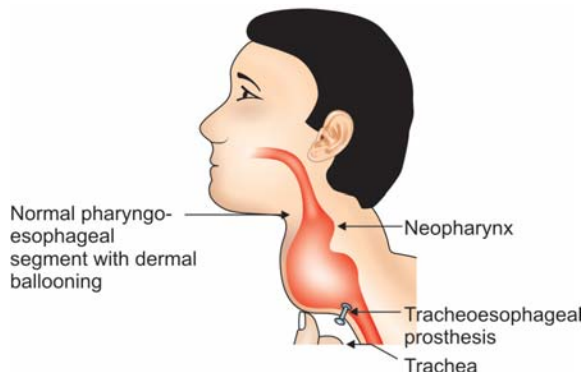
**Fig. 1:** Anterior view showing the rising air column. Arrow marks the proximal end of the spasmodic segment



**Fig. 2:** Lateral view: Arrow marks the spasmodic segment commencement



**Fig. 3:** Videofluoroscopic image showing the spasmodic segment



**Fig. 4:** Lateral view: Normal pharyngoesophageal segment

with PES. In these patients, the trial lignocaine block was injected specifically at these points medial to the carotid vessels. Improvement in speech following the block was observed, and was further confirming using a videofluoroscopy.

All patients who received the lignocaine block showed an excellent response, and were able to develop fluent speech within minutes following injection of lignocaine, thus confirming the PES. These patients were thus deemed eligible for injection with botulinium toxin. 10 of the 14 patients received botox injections. 7 patients showed an excellent speech quality following botox injections (15 to 20 uninterrupted syllables), 2 patients showed minimal improvement and subsequently required 2nd injection of botox, with development of a good speech quality. One patient had a very poor speech quality mainly due to lack of motivation and primarily using tongue driven speech.

## DISCUSSION

TEP speech continues to be a vital armamentarium in the surgical voice rehabilitation of patients undergoing a total laryngectomy. The mechanism of voice production in these patients following total laryngectomy with TEP is well described and known to originate from the vibrating PE segment through the lung powered speech.<sup>6</sup>

Despite ample modifications and advances in surgical techniques there still persists a unique group of patients who continue to have a hyper tonic area in the PES. This frequently manifests in the form of poor voice quality or sometimes failure to develop speech.<sup>6</sup> In these patients, the esophagus distends with air on attempted phonation. However, there is failure to relax the spastic PE segment, which prevents airflow through pharynx.

Trial lignocaine block is an important diagnostic tool in the patients with a hyperfunctioning pharyngoesophageal segment. It also acts as a rough guide to select patients who may derive benefit from the injection of botox. Following the lignocaine block the effects usually lasts for a span of 1 hour, following which the effect of lignocaine wanes off. Despite its utility to confirmatory the spasmodic segment, it seldom guides the surgeon to the mapping of the spasmodic segment. Videofluoroscopic study, in addition to assessment of postlaryngectomy speech, has also been utilized to identify and mark the hypertonic area prior to the injection.<sup>4,5</sup> Another school of thought exists, who have achieved good results by injecting superiorly at the junction between the reconstructed middle constrictor and base of

tongue, and inferiorly at the lower PE segment adjacent to the tracheostoma and a third point between the first two points.<sup>6</sup> However, even with videofluoroscopy the surface markings may not exactly correspond to the spasmodic area.<sup>6</sup> Hence, usually the injection is performed 1cm above and below the marking done on fluoroscopy.

The only reported complication reported in literature following botulinum A injection is dysphagia. This could possibly occur due to hypotonicity of the segment following injection usually if bilaterally given, as it would amount to a bilateral neurectomy.<sup>4</sup>

Our technique of using the visible PE air column height gives a clinical idea of the proximal end of the hypertonic segment. This simple technique identifying the PES not only works in a supple neck but can also be utilized in neck treated with radiation, as majority of the patients in this series were advanced T4 tumors of the larynx and hypopharynx who received postoperative radiotherapy. However, this technique may not work in patients with significant fibrosis following radiotherapy or surgery. In this way, it helps us perform a more targeted injection, avoiding injection to normal segments. It also serves as an objective measure of improvement post injection. This technique shows

promising utility in clinical detection of the spasmodic segment. However, further focused studies in this area are mandatory before concluding on any affirmative assertions.

TEP – Tracheoesophageal puncture

PES – Pharyngoesophageal spasm.

## REFERENCES

1. Genden EM, Ferlito A, Silver CE, Jacobson AS, et al. Evolution of the management of laryngeal cancer. *Oral Oncol* 2007; 43(5):431-39.
2. Bayles SW, Deschler DG. Operative prevention and management of voice limiting pharyngoesophageal spasm. *Otolaryngol Clin N Am* 2004;37:547-58.
3. Hoffman HT, Fischer H, VanDenmark D, et al. Botulinum neurotoxin injection after total laryngectomy. *Head Neck* 1997; 19:92-97.
4. Hamaker RC, Blom ED. Botulinum neurotoxin for pharyngeal constrictor muscle spasm in tracheoesophageal voice restoration. *Laryngoscope* 2003;113:1479-82.
5. Lewin JS, Bishopleone JK, Forman AD, et al. Further experience with botox injection for tracheoesophageal speech failure. *Head Neck* 2001;23:456-60.
6. Chao SS, Graham SM, Hoffman HT. Management of pharyngoesophageal spasm with botox. *Otolaryngol clin N Am* 2004;37:559-66.