

# Partial Bipaddling of PMMC Flap in Full Thickness Cheek Defects involving Lip Commissure: A Novel Technique

Pankaj Chaturvedi, Poonam Joshi

## ABSTRACT

The reconstruction of cheek along with large lip commissural defect after excision of primary tumor is still a challenge. Though primary reconstruction with microsurgical technique is the preferred method, due to infrastructural constraints in developing countries it cannot be offered to all the patients. A number of other techniques have been described earlier, but some of them lead to microstomia, whereas other leads to oral incompetence or poor esthetic outcomes. We are proposing a novel technique of partial bipaddling of pectoralis major myocutaneous (PMMC) flap for reconstruction of such defect. This reconstruction procedure is technically less demanding with an acceptable cosmetic and functional outcome.

**Keywords:** Oral cancer, Lip commissure defect, Bipaddle PMMC.

**How to cite this article:** Chaturvedi P, Joshi P. Partial Bipaddling of PMMC Flap in Full Thickness Cheek Defects involving Lip Commissure: A Novel Technique. *Int J Head Neck Surg* 2013;4(3):113-114.

**Source of support:** Nil

**Conflict of interest:** None declared

## INTRODUCTION

The reconstruction of cheek along with large lip commissural defect as an esthetic and functional unit is still a challenge faced by many surgeons after excision of primary tumor. Primary reconstruction of such defects with microsurgical techniques is now the established protocol in major cancer centers. But in view of infrastructural constraints in developing countries, such a labor intensive reconstruction cannot be offered to all the patients. It is well known that primary closure of such a defect may lead to microstomia. An estlander flap can be attempted when the lip loss is unequal between upper and lower lips. An estlander flap with equal loss may cause not only microstomia but also an eccentric stoma. A combination of pectoralis major myocutaneous (PMMC and deltopectoral flap can cover the defect but is associated with donor site morbidity and unsatisfactory (functionally and esthetically) commissural reconstruction. Folded PMMC flaps have also been utilized that invariably leads to oral incompetence. Forehead flap, popular in the past, is usually best avoided because of poor esthetic results. We here describe a novel technique of partial bipaddling of PMMC flap for full thickness cheek defects involving the lip commissure.

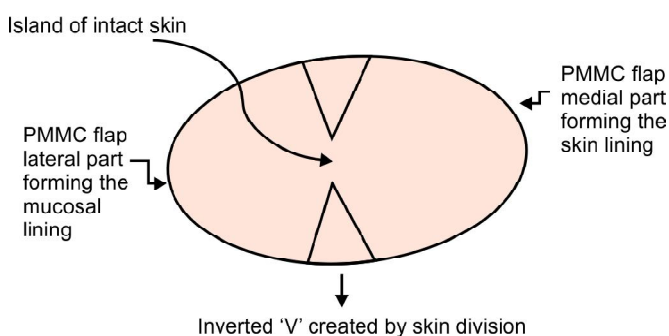
## PROCEDURE

The size of the skin defect and the mucosa defect is measured and the skin paddle over pectoralis major is marked. PMMC flap is elevated in the conventional manner. The flap is pulled into the neck and inserted in the defect in such a way that the lateral part of the skin paddle covers the mucosal defect and the medial part of the skin paddle covers the skin defect in the cheek. Now, instead of complete bipaddling the flap which requires division of the skin and subcutaneous tissue (up to the muscle) as described earlier,<sup>1,2</sup> we do a partial bipaddling of the flap leaving an island of intact skin to form the lip commissure (Fig. 1). This partial bipaddling should preferably be done from the lower edge to accommodate the lower lip within the inverted 'V' created by skin division (Fig. 2). The patients are allowed orally by 5 to 7 days and nasogastric tube is removed. All patients do have signs of oral incompetence in first 1 or 2 weeks but reaches normaly in 3 to 4 weeks. The postoperative results in terms of cosmesis and mouth opening are acceptable (Fig. 2).

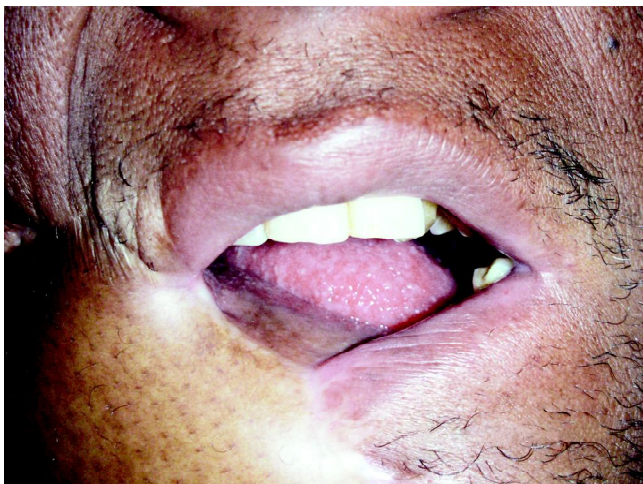## DISCUSSION

Ever since Stephan Ariyan first described the use of PMMC flap for head and neck reconstruction, in 1979,<sup>3</sup> it has become the workhorse of head and neck cancer surgery. Owing to the relative ease of its harvesting, sturdy nature, reliable vascularity and ability to provide bulk, various modifications of this flap have been advocated over time to adapt to the various intricacies of the recipient site such as an osteomyocutaneous variety,<sup>4</sup> innervated flap,<sup>5</sup> bipaddle flap<sup>1</sup> to name a few.

The skin paddle of a PMMC flap is supplied by the perforating vessels from the muscle that traverse through the intervening fat and breast tissue. A bipaddle PMMC has been shown to be technically easy and based on sound anatomic



**Fig. 1:** Partially bipaddled PMMC flap with island of intact skin



**Fig. 2:** Postoperative results with partial bipaddle PMMC flap

concepts.<sup>1,2</sup> Even though primary closure of the lip commissure is often advocated for competence of oral cavity after surgery, it can lead to microstomia that can get progressive over time (more so with co-existent submucous fibrosis). Partial bipaddling of PMMC for commissural reconstruction reduces the problem of incompetence without compromising on the adequacy of mouth opening (Fig. 2). So we propose further modification of bipaddle PMMC flap to reconstruct lip commissure along with full thickness cheek and mucosa defect.

## REFERENCES

1. Ahmad QG, Navadgi S, Agarwal R, et al. Bipaddle pectoralis major myocutaneous flap in reconstructing full thickness defects of cheek: A review of 47 cases. *J Plast Reconstr Aesthet Surg* 2006;59:166-73.
2. Bhathena HM, Kavrana NM. The folded, bipaddled pectoralis major composite flap in oral reconstruction. *Br J Plast Surg* 1989;42:441-46.
3. Ariyan S. The pectoralis major myocutaneous flap: A versatile flap for head and neck reconstruction. *Plast Reconstr Surg* 1979; 63:73-81.
4. Cuono CB, Ariyan S. Immediate reconstruction of a composite mandibular defect with a regional osteomusculocutaneous flap. *Plast Reconstr Surg* 1980;65:477-83.
5. Sachs ME, Conley J, Rabuzzi DD, Codosh P. The kinetic topography of the pectoralis major muscle related to dynamic reconstruction of the head and neck. *Plast Reconstr Surg* 1984; 137:945-50.

## ABOUT THE AUTHORS

### Pankaj Chaturvedi (Corresponding Author)

Professor, Department of Head and Neck Surgery, Tata Memorial Hospital, Mumbai, Maharashtra, India, e-mail: pankajch37@yahoo.com

### Poonam Joshi

Senior Registrar, Department of Head and Neck Surgery, Tata Memorial Hospital, Mumbai, Maharashtra, India