

# The Modified Hockey-Stick Incision for Neck Dissection

<sup>1</sup>Jay Goswamy, <sup>2</sup>Praduman Murthy

## ABSTRACT

The treatment of cancers of the head and neck often involves removal of selected lymph node groups in the neck. It may also include sacrifice of structures within the neck in order to achieve clearance of disease. To make this possible, one must first gain adequate access to the neck. There are many techniques described in the literature to achieve this. This article will describe some common incisions and will discuss their strengths and pitfalls. It will also explain in detail the authors' experience of the 'modified hockey-stick incision' and will explain why it is recommended.

**Keywords:** Neck incision, Oral cavity, Oropharynx, Larynx, Hypopharynx, Thyroid, Parotid.

**How to cite this article:** Goswamy J, Murthy P. The Modified Hockey-Stick Incision for Neck Dissection. *Int J Head Neck Surg* 2014;5(1):22-24.

**Source of support:** Nil

**Conflict of interest:** None

## INTRODUCTION

Neck incisions have been discussed and described in the literature for over a century. In 1906, Crile's landmark paper described a Y-shaped incision,<sup>1</sup> which was in general use for decades, modifications of which are in common use today. Since the 1950s single transverse incisions were used. This led to the development of the MacFee incision,<sup>2</sup> which comprises two parallel horizontal incisions. The traditional hockey-stick incision commences at the mastoid tip extending inferiorly posterior to the anterior border of the trapezius, across the acromioclavicular junction running medially inferior to the clavicle toward the sternum.<sup>3</sup>

The incision as described by Crile and others incorporating a trifurcation point are desirable due to their unparalleled exposure. They are however limited by the trifurcation point itself, which is at risk of marginal necrosis due to poor vascular supply.<sup>3</sup> Necrosis of skin flaps at the critical point

where the three flaps interdigitate can lead to exposure of the underlying carotid artery, with the potentially fatal risk of carotid blowout.<sup>4</sup>

Single linear incisions are cosmetically excellent as they lie in relaxed skin tension lines and as a result of this and the lack of trifurcation point heal very well. However, as MacFee commented when describing his incision even with two parallel incisions, access is limited. As a result disease clearance may be compromised.<sup>2</sup>

The ideal incision should allow good healing of skin flaps, with adequate access, acceptable cosmetic outcome, coverage of the common carotid artery and adaptability if extension is required.<sup>5</sup> Infection, dehiscence, carotid exposure and scar contraction limiting movement are all undesirable outcomes used to quantify failure of technique.

Cervical metastases from squamous cell carcinoma of the laryngopharynx and oropharynx are common and often bilateral. When the treatment of choice is radiotherapy an N0 or N1 neck can be successfully treated with radiotherapy alone. However, in more advanced disease therapy should include surgical removal of all nodal groups at risk by means of a neck dissection. Oropharyngeal malignancy most commonly affects groups II to V. In laryngopharyngeal malignancy, the nodes at greatest risk are II to IV and VI.<sup>6</sup>

## MATERIALS AND METHODS

Between 2003 and 2011, 64 patients underwent unilateral neck dissection as a sole procedure using a modified hockey-stick incision. Patients who underwent neck dissection in addition to surgery for resection of the primary malignancy were excluded from the study. Twelve patients were staged preoperatively as N0, 16 were staged N1, 28 were staged N2 and 8 were staged N3. Eight patients underwent levels I to V dissection, 14 underwent levels II to V dissection, 14 underwent levels I to IV dissection and 28 patients underwent levels II to IV dissection.

A modified hockey-stick incision can be used to expose levels II to V lymph node groups associated with cancers of the pharynx, larynx and midline visceral structures. This can be extended bilaterally creating a broad based apron flap for bilateral neck dissection.<sup>4</sup> The result is a superiorly based subplatysmal flap with no trifurcation points supplied by the cutaneous branches of the facial artery.

After antiseptic preparation and draping of the skin the incision is carefully marked on the skin (Fig. 1). A 12-gauge

<sup>1</sup>Specialty Registrar, <sup>2</sup>Consultant

<sup>1,2</sup>Department of Otorhinolaryngology, Head and Neck Surgery North Manchester General Hospital, United Kingdom

**Corresponding Author:** Jay Goswamy, Specialty Registrar Department of Otorhinolaryngology, Head and Neck Surgery North Manchester General Hospital, Delaunays Road M8 5RB, United Kingdom, Phone: +44-1617202840, e-mail: jaygoswamy@gmail.com

needle is used to tattoo points on the skin either side of the incision with methylene blue (methylthionium chloride) to assist closure at the end of the procedure.

The incision begins at the mastoid tip and extends inferiorly and medially parallel to the posterior border of the sternocleidomastoid muscle (SCM). The incision curves toward the midline in the mid-region of the posterior triangle parallel to and 3 cm above the clavicle and ends at the anterior border of the sternal head of the SCM. A series of Allis forceps are used to hold the platysma whilst a monopolar diathermy Colorado needle (Stryker, USA) is used to raise the flaps in a bloodless plane. The superior flap is first raised to expose levels II, III and IV and tissue as far as the midline. A posteroinferior flap can be raised exposing level V, inferiorly to the clavicle and posteriorly to the anterior margin of the trapezius if a full level V dissection is required. The flaps are held in position with a series of lone-star retraction hooks (Fig. 2). At this point, there is adequate exposure to begin dissection of the at-risk lymph nodal groups. Access to the most anterior aspect of level I is possible from this incision with further retraction anterosuperiorly.

The incision can be extended in its anteroinferior aspect for further exposure. Superiorly, the incision can be extended into the preauricular sulcus to expose the parotid gland. Medial extension allows incorporation of dissection of midline structures including thyroidectomy and laryngectomy. Care however, must be taken to avoid a sharp angle to the curve, which would result in a narrow apex and compromise venous return resulting in edema and potential marginal flap necrosis. If the formation of a stoma is to be included it should be separate from the incision to avoid trifurcation points.

Once the dissection is completed, a size of 14 Redivac drain is inserted into each dissected side and secured with a 3-0 silk suture. The platysma is closed, initially along the points marked with methylene blue, with 4-0 vicryl creating an airtight seal. The skin is then closed with titanium surgical staples ensuring precise apposition of skin edges (Fig. 3). The drain remains in place until there is less than 25 millilitres drained in 24 hours. The staples are removed at 7 days.

## RESULTS

Of the 64 patients, there were two wound infections requiring oral antibiotics and two hematomas requiring surgical drainage. There were no wound breakdowns, chyle leaks or carotid complications. Follow-up in disease-free patients is 5 years in our department.

## DISCUSSION

In selecting this incision as our preferred method, there were several considerations. The base of the flap requires

a consistent arterial supply and venous drainage patterns were also considered. Good exposure without a trifurcation point was deemed important. We also considered patient feedback an important indicator of successful technique.

We have found that the perfusion of this flap was adequate capitalizing on the cutaneous branches of the facial

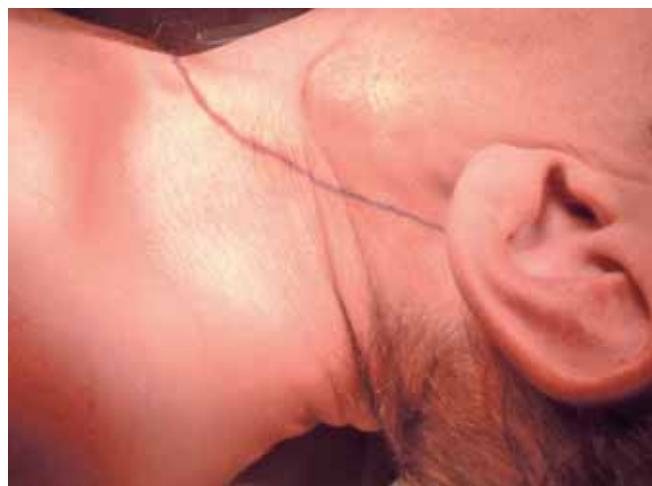

Fig. 1: Marking the incision

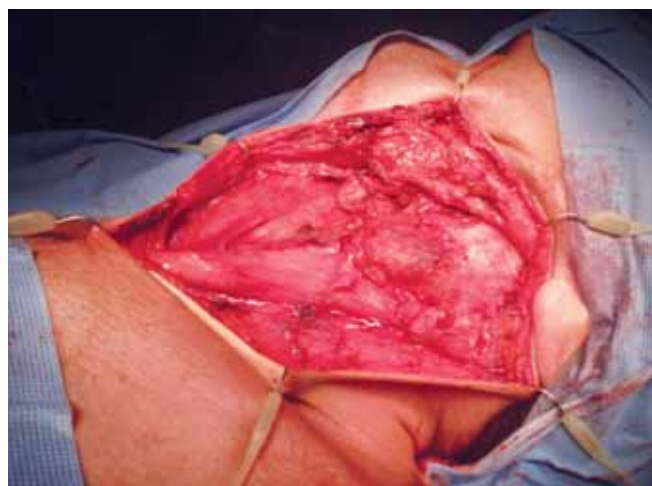


Fig. 2: Exposure of levels II, III, IV and V

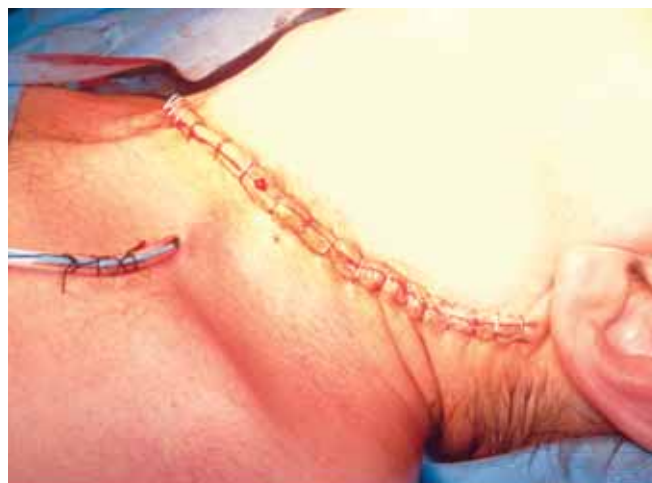
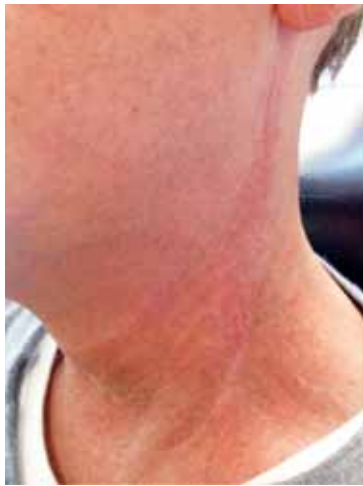
Fig. 3: Closure of neck



**Fig. 4:** Six months postoperative appearance in a patient with a previously irradiated neck

artery to supply the flap in a superoinferior direction. This is demonstrated by a lack of wound breakdown in our patient group. This consistent arterial supply is of particular importance in the previously irradiated neck.

This incision is predominantly vertical and aids venous drainage, which is predominantly from superior to inferior. As such, predominantly transverse incisions have a tendency to result in significantly greater edema, which is a major cause of flap separation.

The lack of trifurcation point in this incision is beneficial. When single incisions have been compared to those with trifurcation points a statistically significant increase in wound dehiscence was described in the latter group. Even in those having surgery following neck irradiation, the only group that had an increase in wound dehiscence was those with trifurcation points.<sup>4</sup>

We have found access to level I is possible, but can be restrictive using this incision. If a level I dissection is to be performed and platysma needs to be taken as part of the resection, the vascular supply of the base of the flap may be compromised. In this situation, a different incision should

be performed; a reversed-hockey-stick incision has been reported as a viable alternative.<sup>3</sup>

We have received a high degree of positive feedback from our patients, who having met patients with a variety of incisions prior to surgery have reported satisfaction with their rate of healing and long-term cosmetic outcome (Fig. 4).

The modified hockey-stick incision has not previously been described for use in surgical treatment of disease in all nodal levels in the neck. In our series, we have demonstrated that this incision can be used successfully for all N-stages of neck disease including radical neck dissection.

We found that the modified hockey-stick incision combines the benefit of excellent intraoperative exposure, good cosmetic outcome, low rates of marginal necrosis and good coverage of the common carotid artery.

This incision is reliable, versatile and well tolerated. We would recommend use of this incision in the surgical treatment of the neck in malignancies arising from the pharynx, larynx and midline visceral structures. An extended incision is recommended in treatment of parotid and thyroid malignancies.

## REFERENCES

1. Crile G. Excision of cancer of the head and neck, with special reference to the plan of dissection based on 132 patients. *JAMA* 1906;47:1780-1786.
2. MacFee WF. Transverse incisions for neck dissection. *Ann Surg* 1960;151:279-284.
3. Omura S, Bukawa H, Kawabe R, Aoki S, Fugita K. Comparison between hockey-stick and reversed-hockey-stick incision: gently curved single linear neck incisions for oral cancer. *Int J Oral Maxillofac Surg* 1999;28(3):197-202.
4. Yui NW, Patel SG, Williamson P, Breach NM. Use of apron flap incision for neck dissection. *Plast Reconstr Surg* 1999;103(6):1655-1660.
5. Shaw HJ. A modification of the MacFee incisions for neck dissection. *J Laryngol Otol* 1988;102(12):1124-1126.
6. Thomas RK. Neck metastasis. Gates GA, editor. *Current therapy in otolaryngology head and neck surgery*. 5th ed. Mosby, Incorporated, 1994:309-314.