

Parotid Tumors: How Rare are They?

¹Rajeshwary Aroor, ²Anusha S Shetty, ³Satheesh Kumar Bhandary, ⁴Vadisha S Bhat, ⁵KS Gangadhara Somayaji

ABSTRACT

Objectives: Salivary gland neoplasms are uncommon, but they are of much interest and debate because of their remarkable variability in structure, clinical presentation, and behavior. We have studied 56 cases of parotid tumors and shared our views on the diagnosis and management of these rare tumors.

Materials and methods: Fifty-six patients with parotid swelling presented to us over a period of 5 years. Preoperatively, all these patients were evaluated with fine needle aspiration cytology (FNAC). Depending on the report, they were subjected to further treatment.

Results: Out of 56 cases, 44 (79%) were benign and 12 (21%) were malignant. Pleomorphic adenoma being the commonest benign tumor [32 cases (72%)] and among the malignant tumors, mucoepidermoid carcinoma was the commonest. Parotidectomy is the gold standard treatment for both the benign and malignant parotid tumors.

Conclusion: Parotid tumors are a rare entity. Among which benign tumors are more common than malignant. An accurate diagnosis preoperatively and timely surgical management would reduce the recurrence rate and risk of complications.

Keywords: Parotid tumors, Fine needle aspiration cytology, Parotidectomy.

How to cite this article: Aroor R, Shetty AS, Bhandary SK, Bhat VS, Somayaji KSG. Parotid Tumors: How Rare are They? *Int J Head Neck Surg* 2014;5(3):126-129.

Source of support: Nil

Conflict of interest: None

INTRODUCTION

Salivary gland tumors are relatively rare among head and neck cancers and are morphologically diverse group of lesions. Parotid region is the source of wide variety of non-neoplastic and neoplastic diseases, both benign and malignant. About 80% of the parotid tumors are benign, hence, salivary malignancies are particularly rare, comprising less than 0.5% of all malignancies and about 5% of

cancers of head and neck.¹ Most of the otolaryngologists would have encountered trouble in the preoperative diagnosis of parotid swellings as clinical history and physical examination have a limited role in making the final diagnosis. Though clinical features may play an important role in identifying malignancy in parotid tumors, it is a challenge to the surgeon because of the complexity of classification and the rarity of many entities, which may show a broad spectrum of morphological diversity. Many studies have shown fine needle aspiration cytology (FNAC) to be a safe, rapid, inexpensive and relatively painless procedure with a diagnostic accuracy of more than 75%.² The aim of our study was to know the clinical symptoms followed by appropriate clinical evaluation of parotid tumors so as to provide the best mode of treatment in order to reduce the recurrence rate and postoperative complications and ensure better surgical outcome and survival rates.

MATERIALS AND METHODS

This study was involving 56 cases of parotid swellings presented to the department of ENT of a tertiary medical care hospital from 2008 to 2013. Among 56 patients, 27 were females and 29 were males. Age ranged from 8 to 72 years with mean age of 42.6 years. The sex predilection distribution among the malignant and benign cases is shown in Figure 1. The age distribution is represented in Figure 2.

Out of 56 cases of parotid tumors, 44 were benign and 12 were malignant (Tables 1 and 2). All the patients presented with preauricular swelling pushing the ear lobule upward. Facial nerve function was normal in all benign cases. Three out of 12 malignant cases presented with facial palsy. Overlying skin was intact and normal in all the benign cases. One patient with malignant lesion had skin infiltration. Twenty-five cases had swelling on the left side out of which, 20 were benign and five were malignant. Thirty cases had swelling on the right side out of which, 23 were benign and seven were malignant. One case had bilateral swelling which was a case of warthins tumor. All cases were subjected to preoperative FNAC. Depending upon the preoperative FNAC report, patients underwent parotidectomy.

All the patients were evaluated preoperatively by ultrasonography. Suspected cases of malignancies further underwent computerized tomography or magnetic resonance imaging.

^{1,5}Professor and Head, ²Resident

³Dean, ⁴Associate Professor

¹⁻⁴Department of ENT, KS Hegde Medical Academy, Mangalore Karnataka, India

⁵Department of ENT, Yenepoya Medical College, Mangalore Karnataka, India

Corresponding Author: Rajeshwary Aroor, Professor and Head, Department of ENT, KS Hegde Medical Academy Mangalore, Karnataka, India, Phone: 08242204472, e-mail: rajeshwarisomayaji@gmail.com



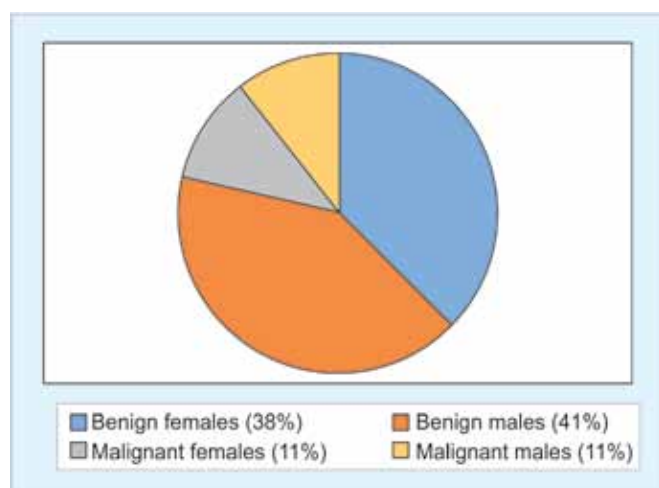


Fig. 1: Sex distribution

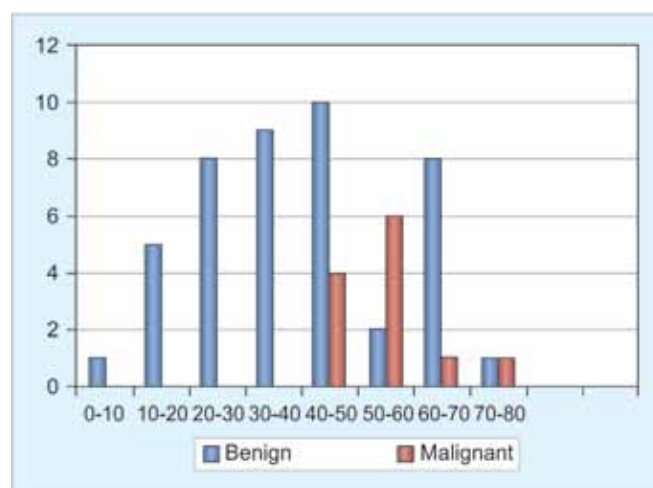


Fig. 2: Age distribution

RESULTS AND OBSERVATION

The fine needle aspiration was corresponding to postoperative histopathological study in 53 cases. In two cases (one case of non-Hodgkin's lymphoma involving the parotid and one case of pleomorphic adenoma), FNAC was inconclusive. One case, diagnosed as pleomorphic adenoma on FNAC, the postoperative histopathology of the specimen revealed to be an intraparotid reactive lymphadenitis.

Among the 44 benign tumors, 32 cases were benign mixed tumor (72%), eight cases were Warthin's tumor and two were oncocytoma, one case of benign spindle lesion, and intraparotid lymph node enlargement in one case (Table 1).

Pleomorphic adenoma was the most common benign parotid gland tumor. Among the malignant tumors, mucoepidermoid carcinoma was the most common (5 out of 12 cases). Four of them were of low grade and one was high grade. All the patients with mucoepidermoid carcinoma underwent total conservative parotidectomy, additional radiotherapy was given in the high grade case in which facial nerve was sacrificed, as facial nerve was involved in that case. Two cases of adenocystic carcinoma underwent radical parotidectomy followed by postoperative radiotherapy. Two cases of acinic cell carcinoma who underwent superficial parotidectomy were followed up till date with no recurrence.

In the case of non-Hodgkin's lymphoma, preoperative fine needle aspiration was inconclusive following which patient underwent superficial parotidectomy. Postoperative histopathological report was suggestive of non-Hodgkin's lymphoma which was of histiocytic type. This was confirmed by immunohistochemistry, being positive for alpha-naphthyl acetate and alpha 1-antitrypsin. Patient underwent postoperative chemoradiation. In two cases of carcinoma ex-pleomorphic adenoma, one patient presented with lymph node metastasis, both the patients

underwent total conservative parotidectomy. Patient with lymph node metastasis was managed with additional neck dissection with postoperative radiotherapy.

Among the five mucoepidermoid carcinoma cases, one case of high grade mucoepidermoid carcinoma was followed up after radiotherapy with no evidence of recurrence till date. Case of non-Hodgkin's lymphoma was followed up for 2 years with no recurrence.

Thirty-two cases of pleomorphic adenoma were managed with superficial parotidectomy. Warthin's tumor was the second most common benign tumor and was managed with enucleation. Three patients followed up for 2 years with no recurrence. The case of benign spindle lesion, underwent superficial parotidectomy, postoperative histopathology was suggestive of neurofibroma. Patient is being followed up till date with no evidence of recurrence.

In one case, preoperatively diagnosed as pleomorphic adenoma by FNAC, postoperative histopathological report after superficial parotidectomy was suggestive of intraparotid reactive lymphadenitis.

The commonest complication observed in superficial parotidectomy is postoperative salivary leak from

Table 1: Distribution of benign tumor

Benign neoplasms	Percentage
Pleomorphic adenoma	32 (72%)
Warthin's tumor	8 (18%)
Oncocytoma	2 (4%)
Neurofibroma	1 (2%)
Intraparotid lymphadenitis	1 (2%)

Table 2: Distribution of malignant tumor

Malignant neoplasms	Percentage
Mucoepidermoid	5 (41%)
Adenocystic carcinoma	2 (16%)
Acinic cell carcinoma	2 (16%)
Carcinoma ex-pleomorphic adenoma	2 (16%)
Non-Hodgkin's lymphoma	1 (8%)

the wound site in the first postoperative salivary leak which was managed with pressure dressing. Commonest complication in total parotidectomy in our study was transient facial paralysis. Facial nerve was sacrificed in three malignant parotid tumors but transient facial palsy was observed mainly in total conservative parotidectomy (in all six cases, four cases of mucoepidermoid carcinoma and two cases of carcinoma ex-pleomorphic adenoma) which was recovered within 3 weeks with facial physiotherapy and steroids. The commonest branch of facial nerve involved was marginal mandibular nerve.

DISCUSSION

Salivary gland neoplasms are a diverse and difficult group of tumors, which are best treated by experienced head and neck surgeons. Eighty percent of all salivary gland neoplasms arise in parotid gland.¹ The parotid tumors can occur in early age groups. Parotid tumors are more likely to be malignant in children than in adults.³ Earliest age in our study was 8 years. Mean age in our study was 42.6 years. Benign neoplasms of parotid are more common in younger age around 45 years.¹ Malignant tumors are primarily a disease of elderly. Patients with parotid tumors over 65 years of age develop cancer at a rate 10 times higher than that of those under the age of 65. But, parotid gland malignancies can present at an earlier age than most other malignancies. In our study, the mean age at the time of diagnosis of malignant neoplasm ranged from 45 to 78 years.

Benign tumors predominate over malignant tumors in parotid gland. Majority of parotid tumors are pleomorphic adenoma.^{1,3} In our study, benign tumors were more common (79%) than malignant tumors (21%). In benign tumors, pleomorphic adenoma was the most common tumor (72%). Among the malignant tumors, mucoepidermoid carcinoma was the commonest (41%).

In parotid tumors, benign tumors are more common in females compared to males, but malignant tumors do not show any sex predilection.⁴ But in our study, benign tumors were more common in males compared to females.

Fine needle aspiration is the most useful diagnostic tool in preoperative evaluation of all parotid tumors. Accuracy of FNAC is not always 100% even in the very best hands. In a clinically suspected benign tumor that is mobile and readily resectable, one can directly go ahead with parotidectomy. We found that FNAC is a gold standard investigation in preoperative evaluation of parotid tumors. But, it is not true in all cases as presence of inflammation may alter the report. And, it also depends on the experience of the pathologists. Not all can get sensitivity of fine needle aspiration as 92.3% and specificity of 97.7% with an

accuracy of 98.14% like in our study. According to literature sensitivity varies from 64 to 99%.⁵

All surgically resectable parotid tumors, other than lymphoma, should be removed by partial or total parotidectomy and preferably the facial nerve should be preserved even in malignant cases.³ Local dissection of benign parotid tumors is a safe procedure with recurrence rates of 2%.³ In our study, all patients who underwent superficial parotidectomy were followed up till date with no recurrence. Malignant cases were treated by total conservative parotidectomy. In the case of lymphoma preoperative fine needle aspiration was inconclusive, postoperative histopathology after superficial parotidectomy was suggestive of histiocytic type of non-Hodgkin's lymphoma which was further confirmed with immunohistochemistry. Patient then underwent radiotherapy which is the treatment option.

Facial nerve is very sensitive to surgical manipulation, and it is not unusual to have temporary weakness of the face, that recovers within a few weeks or months. Permanent weakness is very uncommon with benign tumors.⁶ Out of 47 cases of superficial parotidectomy (44 benign, two cases of acinic cell carcinoma and the case of non-Hodgkin's lymphoma) eight cases had developed transient facial paresis which recovered within 3 weeks. Permanent facial paralysis is commonly associated with malignant parotid tumors.³ Frey's syndrome defined as gustatory sweating due to short circuiting between the secretomotor nerves that supply the parotid gland and sweat glands. The incidence of Frey's syndrome in the literature has been variously described from 6 to 96%.⁷ None of our cases had this complication.

Unlike most other malignancies, salivary malignancies may recur locally or present with distant metastases beyond 15 years after initial treatment.³ Patients with malignant parotid tumors need to be followed up lifelong. Most of our patients are being followed up about till date with no evidence of recurrence.

CONCLUSION

Parotid tumors are rare. Benign tumors being more common than malignant tumors. Among the benign tumors, pleomorphic adenoma is the most common and mucoepidermoid carcinoma being the most common malignant tumor. Highly experienced pathologist play a major role in the preoperative diagnosis of parotid tumors by fine needle aspiration. Hence, a multidisciplinary approach would ensure a good success rate. Careful handling of facial nerve during parotidectomy is must to reduce unnecessary complications. One need not panic on



witnessing salivary leak following superficial parotidectomy as it resolves within 2 weeks with conservative management.

REFERENCES

1. Speight PM, Barrett AW. Salivary gland tumours. *Oral Diseases* 2002;8(5):229-240.
2. Harimath B, Kudva A, Rathore AS. Role of fine needle aspiration cytology in swellings of the parotid region. *Ind J Surg* 2011 Jan-Feb;73(1):19-23.
3. Fagan JJ. A practical approach to parotid tumours. *CME* 2009 Aug;27(8):344-348.
4. Myssiorek D, Ruah CB, Hybels RL. Recurrent pleomorphic adenoma of the parotid gland. *Head Neck* 1990;12(4):332.
5. Awan MS, Ahmad Z. Diagnostic value of fine needle aspiration cytology in parotid tumors. *JPMA* 2004;54(9):617.
6. Eneroth CM, Zajicek J. Aspiration biopsy of salivary tumors, morphologic studies on smears and histological sections from 368 mixed tumors. *Acta Cytol* 1966;10:440-454.
7. Singh N, Kohli M, Kohli H. Innovative technique to reduce incidence of Frey's syndrome after parotid surgery. *Am Surg* 2011 Mar;77(3):351-354.