

Sinonasal Verrucous Carcinoma

¹Sajad M Qazi, ²Irfan Iqbal, ³Aneesa Mirza, ⁴Ihshan Ali, ⁵Sheetal Kumari

ABSTRACT

Verrucous carcinoma is a low grade malignancy and is a variant of squamous cell carcinoma. It is a rare tumor of the sinonasal tract. The neoplasm occurs in older people usually in the seventh or eighth decade of life. Our cases were both of sinonasal origin and of younger age group.

Keywords: Chemoradiotherapy, Sinonasal, Postoperative.

How to cite this article: Qazi SM, Iqbal I, Mirza A, Ali I, Kumari S. Sinonasal Verrucous Carcinoma. *Int J Head Neck Surg* 2015;6(1):8-9.

Source of support: Nil

Conflict of interest: None

INTRODUCTION

Verrucous carcinoma is a rare entity in the sinonasal tract.¹ It was first described and characterized as a distinct entity in 1948 by Ackerman.² Verrucous carcinoma involving the upper aero digestive tract is most in the oral cavity with the glottic larynx being the most frequent nonoral head and neck site.³ Verrucous carcinoma of the nose has been reported to involve the columella,⁴ nasal septum,⁵ nasopharynx⁶ and uncommonly the paranasal sinuses. The incidence varies from 4.5 to 9% and elderly men are most often affected.⁷

DISCUSSION

Verrucous carcinoma is a highly differentiated variant of squamous cell carcinoma.⁸ It has cytological and architectural features similar to that of a reactive process and not that of invasive carcinoma. However, it has the ability to invade normal tissues to a limited extent, demonstrating its aggressiveness.⁹ The gross appearance is usually a warty, grey white lesion with filiform projections. The characteristic histologic features are highly keratinizing surface, papillary areas and apparent absence of dysplastic changes in the squamous epithelium.⁸ Regional lymph node metastasis and distant metastasis are extremely

rare.⁵ Tobacco plays a significant role in the pathogenesis of verrucous carcinoma of the aero digestive tract.² An association between human papilloma virus and verrucous carcinoma has also been proposed. However, results have been inconsistent. Although, human papilloma virus (HPV) types 6, 11, 16 and 18 have been detected to varying degrees in verrucous carcinoma of the oral cavity and the larynx.^{10,11} Orvidas et al could detect no HPV in association with nasal and paranasal sinus verrucous carcinoma using the polymerase chain reaction technique.¹²

The main histopathological differential diagnosis of verrucous carcinoma is from leukoplakia, papilloma, pseudoepitheliomatous hyperplasia, verrucous hyperplasia and highly differentiated squamous cell carcinoma.¹³

Treatment of verrucous carcinoma remains controversial. Surgery is the mainstay of treatment of this neoplasm. Radiotherapy is reported to cause anaplastic change in the tumor within 6 months, making it more aggressive with change of distant metastasis.^{14,15}

CASE REPORTS

Case 1

A 30-year-old female, housewife by occupation presented to our hospital with left nasal obstruction and left nasal anosmia for 1 year. The patient's medical history was unremarkable. Anterior rhinoscopy revealed a greyish white mass which was insensitive to touch in left nasal cavity. Routine laboratory tests were within normal limits. Contrast enhanced computed tomography-paranasal sinuses (CT-PNS) revealed (Fig. 1) contrast enhanced mass involving whole of left nasal cavity an going into inferior margins of orbit. Preoperative biopsy of the nasal mass was suggestive of verrucous squamous neoplasm. Left subtotal maxillectomy, left anterior and posterior ethmoidectomy, left sphenoidotomy, left frontal sinusotomy with orbital floor repair were done. The patient had an uneventful postoperative recovery. Histopathological examination of the surgical specimen showed marked hyperplasia of epidermis with thick bands of parakeratin, bland squamous cells with broad rete ridges suggesting diagnosis of verrucous carcinoma.

Case 2

A 50-year-old male presented with complaints of right nasal obstruction for last 5 months. The patient was operated 2 years back for same complaint by endoscopic approach.

¹Associate Professor, ²Registrar
^{3,5}Postgraduate Scholar, ⁴Lecturer

¹⁻⁵Department of Otorhinolaryngology, Head and Neck Surgery SMHS Hospital, Government Medical College, Srinagar Jammu and Kashmir, India

Corresponding Author: Irfan Iqbal, Registrar, Department of Otorhinolaryngology, Head and Neck Surgery, SMHS Hospital Government Medical College, Srinagar, Jammu and Kashmir India, e-mail: irfaniqbal0809@yahoo.com



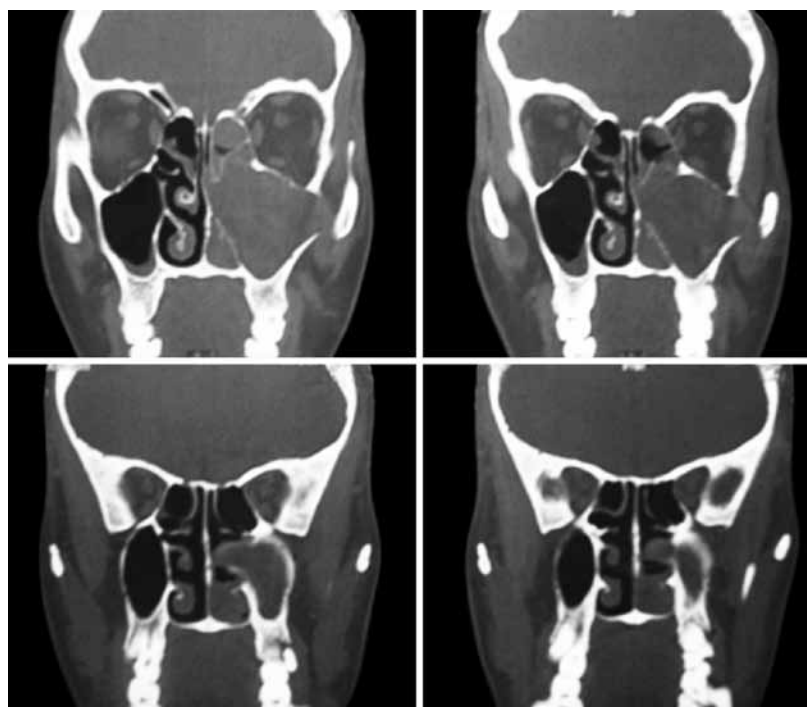


Fig. 1: Contrast enhanced mass involving whole left nasal cavity going into inferior margin of orbit

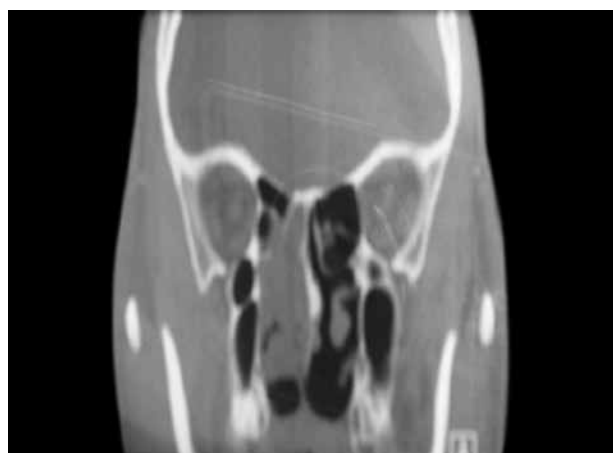


Fig. 2: Contrast enhanced mass involving right nasal cavity involving both anterior and posterior ethmoids

Histopathological examination of the resected specimen showed squamous papilloma. Presently on anterior rhinoscopy, no mass was visualized and contrast enhanced CT PNS showed (Fig. 2) contrast enhanced mass involving radiation therapy (RT). Nasal cavity involving both anterior and posterior ethmoids. Endoscopic excision of mass was planned. Intraoperatively, mass was seen involving right maxilla, anterior and posterior ethmoids, sphenoid and roof of nasal cavity. Postoperative period was uneventful. Postoperative histopathological examination of specimen was compatible with verrucous carcinoma.

REFERENCES

1. Michaels L. Ear nose and throat histopathology. London: Springer Verlag; 1987. p. 171-173.
2. Ackerman LV. Verrucous carcinoma of the oral cavity. *Surgery* 1948;23(4):670-678.
3. Taybos GM, Feltman R, Terezhalmay GT. Verrucous carcinoma invading the orbit: report of a case. *J Oral Med* 1983;38(1):31-34.
4. Vico P, Nagypal P, Rahier I, Derraemaecker R. Verrucous carcinoma of the nasal septum and columella. *Acta Chir Belg* 1997;97(1):50-51.
5. Hanna GS, Ali MH. Verrucous carcinoma of the nasal septum. *J Laryngol Otol* 1987;101(2):184-187.
6. Wolff AP, Ossoff RH, Clemis JD. Four unusual neoplasms of the nasopharynx. *Otolaryngol Head Neck Surg* 1980;88(6):753-759.
7. Spiro RH. Verrucous carcinoma, then and now. *Am J Surg* 1998;176(5):393-397.
8. Michaels L. Ear nose and throat histopathology. London: Springer Verlag; 1987. p. 409-415.
9. Sternberg SS. Diagnostic surgical pathology. Philadelphia PA. Lipincott Raven Publishers; 1996. p. 906-908.
10. Fliess DM, Noble-Topham SE, McLachlin CM, et al. Laryngeal- verrucous carcinoma: a clinicopathologic study and detection of human papilloma virus using polymerase chain reaction. *Laryngoscope* 1994;104(2):146-152.
11. Shroyer KR, Greer RO, Fankhouser CA, et al. Detection of human papilloma virus DNA in oral verrucous carcinoma by polymerase chain reaction. *Mod Pathol* 1993;6(6):669-672.
12. Orvidas LJ, Lewis JE, Olsen KD, Weiner JS. Intranasal verrucous carcinoma: relationship to inverting papilloma and human papilloma virus. *Laryngoscope* 1999;109(3):371-375.
13. Schrader M, Laberke HG. Differential diagnosis of verrucous carcinoma in the oral cavity and larynx. *J Laryngol Otol* 1988; 102(8):700-703.
14. Fonts EA, Greenlaw RH, Rush BJ, Roven S. Verrucous squamous cell carcinoma of the oral cavity. *Cancer* 1969;23(1): 152-160.
15. Biller HF, Bergmann JA. Verrucous carcinoma of the larynx. *Laryngoscope* 1975;85(10):1698-1700.