

ORIGINAL RESEARCH

Primary Mucocutaneous Tuberculosis of Nose: One Decade Study

¹Yamini Gupta, ²Richi Sinha

ABSTRACT

Background: Primary mucocutaneous tuberculosis of nose is extremely rare even in countries with high incidence of pulmonary tubercular disease. The clinicians fail to diagnose its symptoms as primary nasal tuberculosis and, therefore, its treatment is often delayed.

Objective: To elucidate the clinical features and discuss the diagnostic difficulties, management and outcome of primary mucocutaneous tuberculosis of nose.

Materials and methods: A retrospective chart review of five cases of primary mucocutaneous tuberculosis of nose was done over a period of 10 years. The clinical and imaging data, treatments, and outcomes were analyzed in these patients.

Results: Out of five patients of primary mucocutaneous tuberculosis of nose studied during a decade, four were females. The mean age at the time of diagnosis was 24.2 years (12–60 years). The most common presenting symptoms were progressive nasal obstruction, recurrent epistaxis, skin ulceration. All the patients had no signs of pulmonary tuberculosis. All patients had nasal endoscopic guided biopsy for the accurate diagnosis based on histopathology. Biopsy was positive in all the five cases confirming the diagnosis. All the five patients received antitubercular therapy for a period of 6 to 9 months. There was successful response to antitubercular drug treatment. The follow-up for 2 to 7 years showed no relapse, dissemination or death.

Conclusion: Primary nasal tuberculosis is a very rare disease. However, it is important to have a high index of suspicion for nasal tuberculosis in patients presenting with nasal obstruction, epistaxis and skin ulceration especially in countries with high prevalence of tuberculosis.

Keywords: Extrapulmonary tuberculosis, Granulomatous reaction, Primary nasal tuberculosis.

How to cite this article: Gupta Y, Sinha R. Primary Mucocutaneous Tuberculosis of Nose: One Decade Study. *Int J Head Neck Surg* 2015;6(2):69-72.

Source of support: Nil

Conflict of interest: None

¹Assistant Professor, ²Resident

^{1,2}Department of Otorhinolaryngology Head and Neck Surgery MGM Medical College and MY Hospitals, Indore, Madhya Pradesh, India

Corresponding Author: Yamini Gupta, Assistant Professor Department of Otorhinolaryngology Head and Neck Surgery 101, Dilpasand Park, 15/8 New Palasia, Indore, Madhya Pradesh, India, Phone: 919893163830, e-mail: dryamini10@gmail.com

INTRODUCTION

Extrapulmonary tuberculosis occurs in 15% of all patients with tuberculosis.¹ Primary nasal tuberculosis is an exceedingly rare manifestation of infection by *Mycobacterium tuberculosis* even in countries with high incidence of pulmonary disease.¹ Tuberculosis of nose usually occur secondary to pulmonary tuberculosis via contagious, hematogenous or lymphatic route or lupus vulgaris of facial skin.² The clinicians fail to diagnose its symptoms as primary nasal tuberculosis and, therefore, its treatment is often delayed leading to morbidity and mortality. In the light of relevant literature, we aim to present here a series of cases that presented with only nasal signs and symptoms. In this type of presentation, one should be suspicious of tuberculosis so that early diagnosis and successful treatment can be given. The basic principle here is to elucidate the clinical characteristics of primary nasal tuberculosis and to discuss diagnostic difficulties.

MATERIALS AND METHODS

A retrospective chart review of all patients with primary mucocutaneous tuberculosis of nose as a primary diagnosis was undertaken from 2003 to 2013 in the department of otorhinolaryngology of our institute. A total of five cases were selected with histopathology confirmed diagnosis. Patients with previous history of tuberculosis or foci elsewhere in the body were excluded from the study. A retrospective search and analysis of the data collected from the medical case sheets of five cases of primary mucocutaneous tuberculosis of nose included patient's demographic details, clinical features with duration of illness, bacteriological, histopathological, radiological (including chest X-ray) and other relevant investigations like venereal disease research laboratory (VDRL), treponema pallidum hemagglutination assay (TPHA), cytoplasmic antineutrophil cytoplasmic antibodies (C-ANCA), and anti-HIV tests, treatment and follow-up.

RESULTS

Case 1

A 22-year-old female complained of intermittent epistaxis and bilateral progressive nasal obstruction for 6 months.

On nasal examination, slough covered multiple pinkish, granular polypoidal tissue was seen filling bilateral nasal cavity which bled mildly on touch. Tissue did not shrink on application of decongestants. There was no skin lesion over nose. The appearance and consistency of the lesions were different from those of nasal polyps. Remaining otorhinolaryngology examination did not reveal any other pathological findings. The laboratory tests indicated erythrocyte sedimentation rate 18 mm/hour. The patient had been given a BCG vaccination when she was a child. VDRL, TPHA, C-ANCA, and anti-HIV tests were found negative. Other biochemical tests, as well as chest X-ray were also normal. Patient did not have any documented history of pulmonary tuberculosis and diabetes mellitus or any known immunologic problems to include human immunodeficiency virus (HIV) infection, hematologic malignancies or rheumatologic diseases.

Computed tomography (CT) scan of paranasal sinus (PNS) revealed circumferential mucosal thickening involving both maxillary sinuses extending into infundibulum and blocking the ostium. Polypoidal soft-tissue density lesions were seen occupying the anterior nasal cavity bilaterally (Fig. 1).

Diagnostic nasal endoscopy was done which revealed multiple, pinkish polypoidal tissue involving both nasal cavities with cheesy material in posterior part of nasal floor. The biopsy of lesion was taken, and sent for histopathological and microbiological (bacterial, fungal and mycobacterial) examination. Subsequent Ziehl-Neelsen staining revealed acid-fast bacilli (AFB). The histopathologic examination revealed caseating granulomatous lesion, inflammation with epithelioid cells, lymphocytes and few giant cells (Fig. 2). These findings suggested nasal tuberculosis. So, the patient was administered isoniazid (5 mg/kg), rifampicine (10 mg/kg),

pyrazinamide (25 mg/kg), and ethambutol (15 mg/kg) for 2 months, followed by isoniazid (5 mg/kg) and rifampicine (10 mg/kg) for 4 months. At the end of the treatment, the lesion completely disappeared.

Case 2

A 60-year-old female patient presented to ENT OPD with diffuse swelling over nose for 2 years and ulcer below tip of nose for 1 year local examination revealed a diffuse swelling involving the nasal tip and supratip area was studded with multiple deep seated papules. There was a destructive lesion 1 × 1 cm involving the columella (Fig. 3). Systemic examination was unrewarding. There was no lymphadenopathy. Provisional diagnosis of lupus vulgaris and midline lethal granuloma were made and the patient investigated. Chest X-ray and X-ray of PNS were normal. Mantoux was positive but sputum for AFB negative. Wedge biopsy revealed a granulomatous lesion with Langerhans cells, consistent with tuberculosis. Patient was put on 9 months Antituberculosis treatment (ATT) and responded dramatically to therapy.

Case 3

A 12-year-old girl presented to ENT department with progressive swelling over tip of nose for 2 years. For the last 1 year, she was having progressive nasal blockade and sporadic scanty epistaxis. Her mother died of pulmonary tuberculosis 5 years back. There were multiple small papilla over nasal tip and supra tip extending to both ala, destroying columella causing the tip to face down (parrot beak nose). Also, there were multiple polypoidal tissue present in both nasal cavities. A provisional diagnosis of tuberculosis was made and patient investigated. Hematological profile was normal other than mild anemia

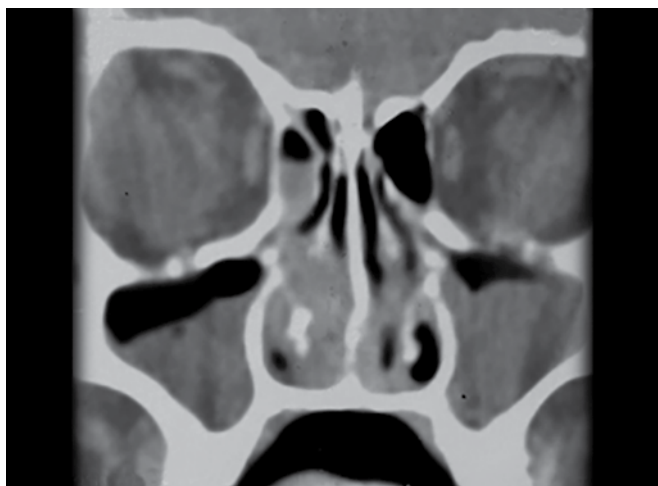


Fig. 1: Paranasal sinus tomography showing hyperdense soft-tissue mass in bilateral nasal cavity with extension into bilateral maxillary sinus and ethmoid sinus on the right side

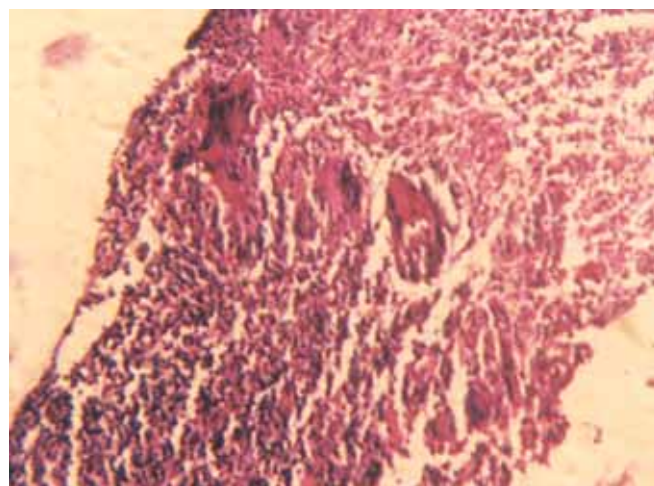


Fig. 2: Microscopic photograph in high power with hematoxylin and eosin-stained sections showing caseating granulomatous lesion with few giant cells

(Hb 10 gm%) and raised ESR. Mantoux test was positive. Chest X-ray did not show any evidence of tuberculosis. VDRL and ELISA for HIV were negative. Nasal swab for AFB was positive. Endoscopic biopsy from nasal cavity and nasal skin revealed caseating granuloma consistent with tuberculosis. Patient responded to 6 months ATT dramatically.

Case 4

Eleven years male was referred to us from to pediatric OPD with complaints of nonhealing ulcer over nose for last 6 months. Progressive nasal blockage associated with perverted sense of smell and hyponasal voice for last 6 months. On examination, destructive lesion of 1 × 2 cm was present over columella with groups of reddish-brown papules over tip of nose and both ala nasi (Fig. 4). On diascopy, classical apple-jelly nodule was seen. Systemic examination was within normal limits. Hematology showed moderate lymphocytosis, mild anemia, raised ESR. X-ray chest was normal. Sputum for AFB was negative. Mantoux test was positive. Histopathology after biopsy showed granulomatous lesion with Langerhan's giant cells suggestive of tuberculosis.

Case 5

A 16-year-old girl, a known case of juvenile diabetes mellitus, presented with a nonhealing ulcer over the nose for 7 months which expanded rapidly. Local examination showed right ala and columella to be destroyed and the floor of right nasal cavity exposed. Systemic examination was of no significance. There was no lymphadenopathy. Chest X-ray and X-ray PNS were normal. Hematological profile showed raised ESR, patient achieved euglycemia with regular insulin therapy. VDRL was negative. Sputum for AFB and Mantoux were also negative. Wedge

biopsy of lesion revealed a caseating granulomatous lesion consistent with tuberculosis. Patient responded to 9 months ATT.

The clinical profile of all five patients is summarized in Table 1. Out of five patients of primary mucocutaneous tuberculosis of nose studied during a period of 10 years from 2003 to 2013, four were females. The mean age at the time of diagnosis was 24.2 years (12–60 years). The most common presenting symptoms were nasal obstruction, recurrent epistaxis, skin ulceration. All the patients had no signs of pulmonary tuberculosis. Ziehl-Neelsen staining for acid fast bacilli was positive only in one case. All patients had positive nasal endoscopic guided biopsy for the accurate diagnosis and the diagnosis was based on histopathology.

All the five patients received antitubercular therapy for a period of 6 to 9 months. There was successful response to antitubercular drug treatment. The follow-up observation of patients who had already finished their treatments lasted from 2 to 7 years, and there was no relapse, dissemination or death in any of these patients.

DISCUSSION

Primary mucocutaneous tuberculosis of the nasal region is one of the rarest forms of extrapulmonary tuberculosis but, still poses a significant clinical and diagnostic challenge. Nasal tuberculosis was first reported in 1761 by Giovanni Morgani, who described autopsy findings of a young man with ulcerative lesions in the soft palate, nasopharynx, and nasal cavity.² It usually occurs secondary to pulmonary Koch's via contagious, hematogenous or lymphatic routes. Otherwise, organisms may be introduced into the nose by inhalation of infected droplets or dust. Primary cases are very rare despite the increase in extrapulmonary tuberculosis.³ In a review of 20th century

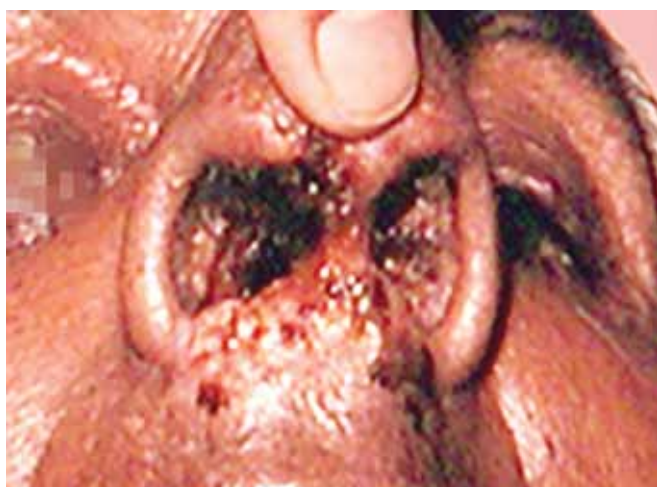

Fig. 3: Nasal tip and supratip area studded with multiple papules and destruction of columella

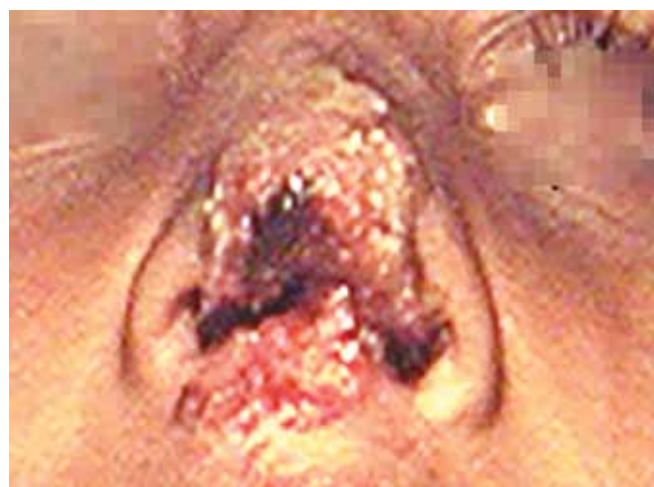

Fig. 4: Ulcer over nose with destruction of columella and reddish-brown papules over tip of nose and both ala nasi

Table 1: Clinical profile of all five patients

Features	1	2	3	4	5
Age and sex	22 years/ female	60 years/ female	12 years/ female	11 years/ female	16 years/ female
Nasal obstruction	+	-	+	+	-
Epistaxis	+	-	+	-	-
Hyponasal voice	-	-	-	+	-
Perverted sense of smell	-	-	-	+	-
Ulceration and tissue destruction	-	+	+	-	+
Polypoidal tissue in nasal cavity	+	-	-	+	-
ZN staining for AFB	+	-	-	-	-
Biopsy	+	+	+	+	+
Response to treatment	+	+	+	+	+

medical literature published in 1997, Butt found only 35 cases of primary nasal tuberculosis. The reason for the scarcity of nasal tuberculosis is not clearly established. Probably, normal respiratory mucous membrane is markedly resistant to invasion by the tubercle bacillus. The mechanical protection offered by the cilia as well as an apparent bactericidal effect of the nasal secretions also plays an important role.⁵ Studies of the nasal tuberculosis show that usually, females are more susceptible than males. Similar was the case in our study. The middle-aged and elderly seems to be the most frequently affected compared to any other age group⁵ as against this we had more cases in young age group of 10 to 25 years. Here, the lesion was bilateral in four out of five cases unlike most unilateral cases generally reported in literature. The most common complaints associated with primary nasal tuberculosis are nasal obstruction, blood stained rhinorrhea, sometimes frank epistaxis, and recurrent polyps and mucosal and skin ulcerations.⁴ It mainly affects the anterior parts of the nasal cavity, commonly the nasal septum. In our cases, it manifested with epistaxis and multiple pink polypoidal tissue simulating polyp and painless ulcerative lesion on skin. Thus, in countries like India, where incidence of tuberculosis is high, in patients presenting with epistaxis and nasal mass with or without skin ulceration tuberculosis should be considered as one of the differential diagnosis. The other differential diagnosis, clinically, for nasal, TB may include lethal midline granuloma, syphilis, leprosy, fungal granuloma, rhinoscleroma and Wegener's granuloma and neoplastic disorders.⁵

The definite diagnosis of tuberculosis is made by isolating *M. tuberculosis*. The histopathological findings, such as caseation and granuloma, which are characteristics of tuberculosis, and the patient's response to treatment also

indicated diagnosis of tuberculosis. It should be recalled that sometimes tuberculosis could occur with noncaseating granuloma. In these cases, the differential diagnosis should consist of Wegener's granuloma, sarcoidosis, leprosy, mycoses, malignancy and syphilis.

The basic principles that underlie the treatment of pulmonary tuberculosis also apply to nasal tuberculosis. Studies suggest that 6 to 9-month regimens (2 months INH, RIF, PZA and EMB followed by 4 to 7 months of INH and RIF) are effective.⁶ Nasal tuberculosis is known to respond well to the regular treatment for tuberculosis except in places where multidrug resistant tuberculosis is prevalent. In some studies, treatment consisting of three drugs was found to be effective against extrapulmonary tuberculosis. When the community rate of isoniazid resistance is greater than 4%, empiric therapy for disease should consist of four-drug therapy especially in new diagnosed cases.⁶

CONCLUSION

Primary nasal tuberculosis is a very rare disease. However, it should definitely be considered in differential diagnosis when a patient presents with nasal obstruction, epistaxis and skin ulceration as is illustrated by our case series. Since diagnosis is often based on histopathologic findings an endoscopic biopsy is must. Nasal tuberculosis is known to respond well to the regular treatment for tuberculosis, thereby its timely diagnosis can prevent morbidity and mortality.

ACKNOWLEDGMENT

Authors acknowledge Superintendent, MY Hospital, for permitting to use hospital records and Senior Faculty of Staff Dr YK Maru, Professor and Head, and Dr RK Mundra, Associate Professor, for their support and guidance.

REFERENCES

1. Thakur JS, Chauhan I, Mohindroo S, et al. Primary nasal tuberculosis. Clin Rhinol Int J 2011 Jan-Apr;4(1):9-41.
2. Young-Chul C, Yong-Soo P, Eun-Ju J, Seung-Heon S. The disappeared disease: tuberculosis of the nasal septum. Rhinol 38(2):90-92.
3. Dye C, Scheele S, Dolin P, et al. Consensus statement. Global burden of tuberculosis: estimated incidence, prevalence, and mortality by country. WHO Global Surveillance and Monitoring Project. JAMA 1999;282(7):677-686.
4. Butt AA. Nasal tuberculosis in the twentieth century. Am Med Sci 1997;313(6):332-325.
5. Lai TY, Liu PJ, Chan LP. Primary nasal tuberculosis presenting with septal perforation. J Formos Med Assoc 2007;106(11): 953-955.
6. American Thoracic Society; CDC; Infectious Diseases Society of America. Treatment of tuberculosis. MMWR 2003;52(RR11): 1-77.

