

## REVIEW ARTICLE

# Bronchogenic Cyst as a Rare Differential in an Adult Cervical Cystic Swelling

<sup>1</sup>Ajith J George, <sup>2</sup>Pranay Gaikwad

## ABSTRACT

**Introduction:** Bronchogenic cysts are rare congenital malformations of the ventral foregut development usually located in the mediastinum and intrapulmonary regions. Cervical bronchogenic cysts are unusual and have been reported predominantly in the pediatric age population, rarely in adults.

**Materials and methods:** We retrieved and analyzed medical records of all patients who were diagnosed to have bronchogenic cysts within the past 5 years who presented to the surgical departments of pediatric surgery, cardiothoracic, general surgery, ENT, and head and neck surgery.

**Data:** Thirty-three patients with bronchogenic cysts were identified, five of whom were children and only presented with a cyst in the neck. The details of the patient with cervical bronchogenic cyst are presented and discussed.

**Conclusion:** Bronchogenic cysts of the neck are rare differential diagnosis of neck masses in adults. The magnetic resonance imaging was found to be specific for diagnosis and preoperative assessment. Complete surgical excision is the treatment of choice, along with the prevention of future complications and establishment of diagnosis.

### Keywords:

**How to cite this article:** George AJ, Gaikwad P. Bronchogenic Cyst as a Rare Differential in an Adult Cervical Cystic Swelling. *Int J Head Neck Surg* 2015;6(4):175-177.

**Source of support:** Nil

**Conflict of interest:** None

## INTRODUCTION

Bronchogenic cysts are rare congenital malformations of the ventral foregut development. They have been noted in the mediastinum and in intrapulmonary regions. Cervical bronchogenic cysts are unusual and have been reported predominantly in the pediatric age population, rarely in adults.<sup>1,2</sup>

<sup>1</sup>Postgraduate Registrar, <sup>2</sup>Professor

<sup>1</sup>Department of General Surgery, Christian Medical College & Hospital, Vellore, Tamil Nadu, India

<sup>2</sup>Department of Head and Neck Surgery, Christian Medical College & Hospital, Vellore, Tamil Nadu, India

**Corresponding Author:** Ajith J George, Postgraduate Registrar Department of General Surgery, Christian Medical College & Hospital, Vellore, Tamil Nadu, India, Phone: +919894064580 e-mail: ajithjohn00@hotmail.com

**Table 1:** Five-year retrospective data – our experience

Region	Incidence n = 33 (%)
Lung and thorax	32 (97)
Subcarinal	5 (15)
Upper lobe	7 (21)
Lower lobe	2 (6)
Superior mediastinum	4 (12)
Posterior mediastinum	11 (34)
Paratracheal	3 (9)
Neck	1 (3)

We retrieved and analyzed medical records of all patients who were diagnosed to have bronchogenic cysts within the past 5 years who presented to the surgical departments of pediatric surgery, cardiothoracic, general surgery, ENT and head and neck surgery.

Thirty-three patients with bronchogenic cysts were identified, five of whom were children. Table 1 documents the locations of cysts. A significant proportion of patients had their cysts located in the mediastinum.

Only one patient had cervical bronchogenic cyst and discussed in details.

## CASE REPORT

A 39-year-old male presented with a progressively increasing but otherwise asymptomatic swelling in the right side of the neck for 8 months. He was dependent on tobacco, which he habitually chewed. The history did not suggest other medical illness. On examination, his pulse rate was 90/minute and blood pressure was 110/60 mm Hg. There was a soft, nonpulsatile, noncompressible, cystic swelling measuring 6×3 cm<sup>2</sup> posterior to the right sternocleidomastoid muscle extending superiorly up to the level of the thyroid cartilage, with the lower extent not visible and an absent cough impulse. Systemic examination was normal.

On imaging the neck region, ultrasonography showed a well-defined thin-walled cystic lesion measuring 35×17.3×47.5 mm<sup>3</sup> in the right side of the neck with no internal vascularity or any solid component, and features suggestive of a branchial cyst (Fig. 1). A magnetic resonance imaging (MRI) scan revealed a unilocular, thin-walled cystic lesion in the infra-hyoid neck on the right side in the posterior cervical space that appeared hypointense on T1 but hyperintense on T2 and short tau inversion

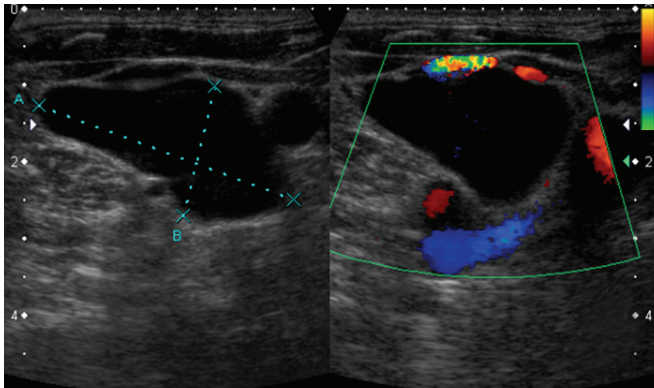


Fig. 1: Ultrasound neck-cystic avascular lesion

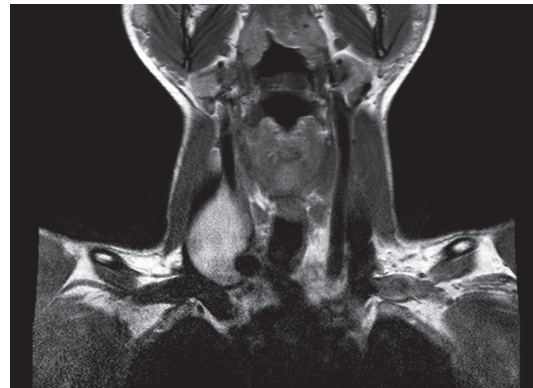


Fig. 2: T2W coronal MRI (findings described above)

recovery images. The lesion was also anterior to the prevertebral muscles and posterior to the common carotid artery and internal jugular vein (IJV) splaying the vessels and compressing the lower end of IJV. In the lower neck the lesion extended along the carotid vessels in close relation to the proximal aspect of subclavian vessels on right side with the IJV-subclavian vein confluence lateral to the cyst and the subclavian artery posterior to the cyst. There was no track or sinus seen with the thyroid, pyriform sinus, or overlying skin. The trachea and esophagus were within normal limits. The differentials considered were a fourth arch branchial cyst or a lymphangioma (Fig. 2).

Excision of the cystic lesion in the right side of the neck revealed, intraoperatively, an 8 × 5 cm<sup>2</sup> unilocular cystic lesion filled with clear watery fluid along the long axis and deep to the right IJV with the findings in consonance with those of the imaging. The lesion was excised completely. The histopathological examination of the surgical specimen revealed a fibrocollagenous cyst wall lined by respiratory epithelium (Fig. 3). The underlying stroma appeared to be mildly edematous, congested, and infiltrated by lymphocytes and a few histiocytes. There were no features suggestive of malignancy.

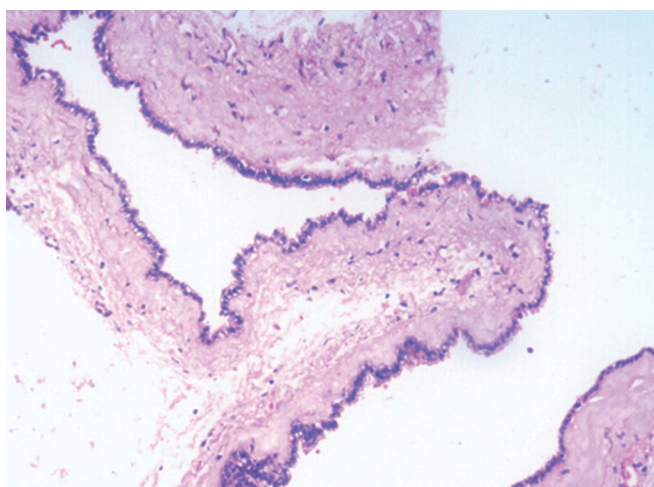


Fig. 3: Hematoxylin and eosin stain, 10× and 20× resolution: Shows fibrocollagenous cyst wall lined by respiratory epithelium

## DISCUSSION

Bronchogenic cysts are rare benign congenital anomalies of the foregut. Foregut duplication cysts form due to persistence of heterotopic rests of the foregut-derived epithelium and can occur anywhere along the upper alimentary tract, most frequently in the thorax or abdomen that contain foregut derivatives. Foregut duplication cysts are classified according to the organs of origin – bronchogenic cyst, esophageal duplication cyst, and enteric duplication cyst. The cyst may contain epithelial types, such as gastric mucosa, ciliated respiratory-type epithelium, stratified squamous epithelium, and simple cuboidal epithelium. Foregut duplication cysts in the head and neck have rarely been reported and their clinical presentation can mimic other masses in the head and neck. Traditionally, there are three HPE criteria that are essential to make the diagnosis of foregut duplication cyst: (1) Be covered by a smooth muscle layer, (2) contain epithelium derived from the foregut, and (3) be attached to a portion of the foregut.<sup>1,2</sup>

In adults, the two most common locations of bronchogenic cyst are the mediastinum and lung parenchyma; 50 to 60% of all mediastinal cysts are bronchogenic cysts. Most bronchogenic cysts are filled with fluid and are usually a unilocular cyst, and are not in communication with the airway. They have ciliated columnar, cuboidal, or pseudostratified epithelial cell layer, with cartilage and respiratory glands and a fibromuscular connective tissue, which identifies them as bronchial in origin. The most reliable criterion for the diagnosis of bronchogenic cyst is the presence of cartilage plates in the wall of the cyst, with submucosal glands and smooth muscles.<sup>1-3</sup>

The present case series from this 5-year retrospective review in our institution identified 33 biopsy-proven operated cases of bronchogenic cysts and has demonstrated the rarity of such lesions in the neck. None of the children in our case series had lesions in the neck. Our findings are consistent with the rarity of the condition as reported by other authors. A review of the literature (using the following search strategy on PubMed) revealed 14 cases

**Table 2:** Reported cases of bronchogenic cysts of neck in adults

Sl. no.	Authors ref.	Age (years)	Sex	Location
1	Dubois (1981)	24	M	Supraclavicular region
2	McManus (1984)	34	M	Between right carotid sheath and tracheoesophageal groove; beginning at cricoid cartilage and extending into mediastinum
3	Rapado (1998)	54	M	Supraclavicular triangle extending into superior mediastinum
4	Barsotti (1998)	49	M	Calcified cystic tumor posterior to the left lobe of thyroid gland
5	Majlis (1999)	44	M	Pretracheal anterior cervical region simulating a thyroid lesion
6	Shimizu (2000)	25	F	Cystic in left lobe through isthmus of thyroid
7	Tanita (2002)	46	M	Mass on left scapular area
8	Hadjihannas (2003)	70	M	Subcutaneous cystic mass on suprasternal notch
9	Al-Kasspooles (2004)	62	M	Neck mass communicating with membranous trachea
10	Newkirk (2004)	20	F	Cystic mass in right lobe of thyroid gland
11	Newkirk (2004)	22	M	Cystic mass extending from inferior pole of right thyroid lobe to superior mediastinum
12	Sanli (2004)	48	F	Cyst in right paratracheal region
13	Ibanez Aguirre (2006)	26	M	Cervical mass to lower pole of thyroid lobe
14	Bocciolini (2006)	57	M	Cyst in right paratracheal region

Source: Moz et al<sup>4</sup>

of bronchogenic cysts of the neck in adults (Table 2). The common sites were in the region of thyroid and paratracheal region followed by the supraclavicular and suprasternal notch. There were 10 cases of cervical bronchogenic cysts reported in the midline region and 4 were located in the lateral aspect of the neck. There was a 4:1 male to female ratio.<sup>4</sup>

Magnetic resonance imaging is the imaging modality of choice and has found increasing usefulness in planning of surgery as it gives excellent soft tissue differentiation.<sup>5</sup>

In adults the differential diagnosis are abscesses, enlarged lymph nodes (predominantly if it has central necrotic), pulmonary lesions, branchial cleft cyst, thyroglossal cleft cyst, vascular anomalies, laryngocoele, schwannoma, and neck metastases. As mentioned by Gaikwad et al,<sup>3</sup> a subcutaneous suprasternal bronchogenic cyst of the neck may be added to the list of transilluminant cervical subcutaneous swellings. This can differentiate it from nontransilluminant cystic neck lesions like branchial cleft cysts, thyroglossal cysts, epidermal inclusion cysts, thymic cysts, thyroid cysts, and teratomas.

Histopathological confirmation is essential for a definitive diagnosis. The lining of bronchogenic cysts is respiratory in origin (i.e., ciliated pseudostratified columnar epithelium overlying a fibrous connective tissue wall containing seromucous subcutaneous glands and cartilage plates). Smooth muscles may be present in the wall.<sup>1-3</sup>

The management would include complete excision in view of a chance of malignant transformation, such as malignant melanoma and mucoepidermoid carcinoma.<sup>6</sup>

## CONCLUSION

Ectopic bronchogenic cysts are rare lesions of the head and neck, especially in the upper lateral neck, and they should be included in the differential diagnosis in the evaluation of congenital neck cysts. Complete surgical excision is the definitive treatment given its low recurrence rate, prevention of future complications, and establishment of a diagnosis. Magnetic resonance imaging is an important preoperative imaging tool.

## REFERENCES

1. Kieran SM, Robson CD, Nosé V, Rahbar R. Foregut duplication cysts in head and neck; presentation, diagnosis, and management. *Arch Otolaryngol Head Neck Surg* 2010 Aug;136(8):778-782.
2. Newkirk KA, Tassler AB, Krowiak EJ, Deeb ZE. Bronchogenic cysts of the neck in adults. *Ann Otol Rhinol Laryngol* 2004 Sep;113(9):691-695.
3. Gaikwad P, Muthusami JC, Raj JP, Rajinikanth J, John GM. Subcutaneous bronchogenic cyst. *Otolaryngol Head Neck Surg* 2006 Dec;135(6):951-952.
4. Moz U, Gamba P, Pignatelli U, D'Addazio G, Zorzi F, Fiaccavento S, Milesi F. Bronchogenic cysts of the neck: a rare localization and review of the literature. *Acta Otorhinolaryngol Ital* 2009 Feb;29(1):36-40.
5. Mehta RP, Faquin WC, Cunningham MJ. Cervical bronchogenic cysts: a consideration in the differential diagnosis of paediatric cervical cystic masses. *Int J Pediatr Otorhinolaryngol* 2004 May;68(5):563-568.
6. Ustundag E, Iseri M, Keskin G, Yayla B, Muezzinoglu B. Cervical bronchogenic cysts in head and neck region: review of the literature. *J Laryngol Otol* 2005 Jun;119(6):419-423.