

REVIEW ARTICLE

Robotic Surgery in Pediatric Otolaryngology

¹Soham Roy, ²Blaine Smith

ABSTRACT

Robotic surgery is becoming increasingly utilized in head and neck surgery. Robotic surgery for Pediatric Otolaryngology, while still in its relative infancy, represents a new advancement that may improve outcomes and decrease morbidity associated with traditional endoscopic procedures. In this chapter, we review the utilization of robotic platforms in Otolaryngology, discuss current literature describing the use of robotic technology for Pediatric Otolaryngology, and explore potential new applications in Pediatric Otolaryngology for robotic platforms.

Keywords: Airway, Pediatric, Robotic surgery.

How to cite this article: Roy S, Smith B. Robotic Surgery in Pediatric Otolaryngology. *Int J Head Neck Surg* 2016;7(2):120-123.

Source of support: Nil

Conflict of interest: None

INTRODUCTION

The utilization of surgical robots to enhance minimally invasive surgery is an emerging technique being increasingly employed in head and neck surgery. Transoral robotic surgery (TORS) is a subject of increasing interest among head and neck surgeons because of the ability to provide a three-dimensional (3D) view of the surgical field, in contrast to the coaxial field of view provided by traditional endoscopic techniques. In addition, surgical robots bypass traditional line-of-sight limitations encountered in transoral endoscopic procedures. Robotic techniques also provide tremor reduction through motion scaling and wristed instrumentation that provides the surgeon with improved dexterity and precision.¹ These advantages of robotic techniques have enhanced the ability to perform transoral surgery, reducing the need for traditional external or open approaches and avoiding the associated morbidity. The increasing adoption of transoral robotic approaches has resulted in fewer perioperative complications, reduced operating room time, shorter postoperative hospital stays, and decreased readmission rates.²

Transoral robotic surgery was initially adopted for head and neck tumor resection, with more recent applications including sleep apnea surgery, transaxillary thyroidectomy, and lingual tonsillectomy. Although robotic surgery is currently approved by the Food and Drug Administration (FDA) only in the treatment of head and neck cancers, it is now being adapted for use in endoscopic pediatric airway surgery. The use of robotic surgery in the pediatric airway poses many challenges, most obviously the difficulty of adapting large robotic instrumentation into the limited space of the pediatric airway. Although initial attempts to access the pediatric airway using TORS were limited by the size of the robotic surgical instruments, recent advancements have resulted in the development of surgical instruments that are more adaptable to the pediatric space (Fig. 1). This decrease in the size of instruments has greatly increased the applications for robotic surgery in the pediatric airway.²

BACKGROUND

The addition of robotic tools is a relatively new development in surgery. The first robotic-assisted surgery took place in 1985, when neurosurgeons used the Programmable Universal Machine for Assembly (PUMA560) to assist in computed tomographic-guided brain biopsies. However, the machine was an industrial robot not designed for surgical purposes, and the parent company refused to promote surgical use of its nonsurgical device in the interest of safety. In 2000, the FDA approved use

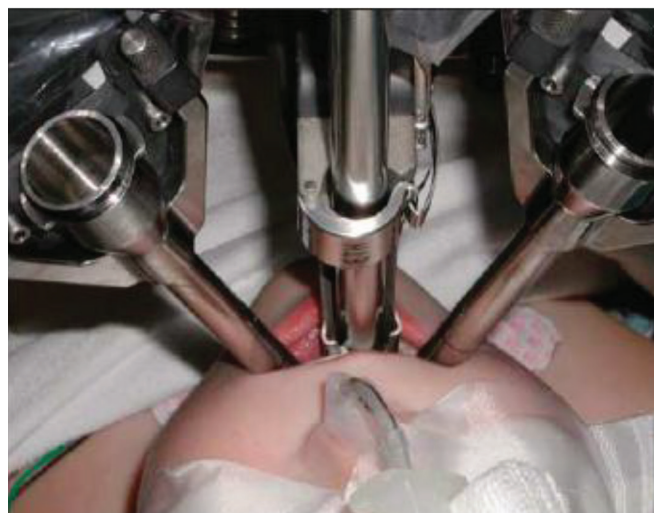


Fig. 1: da Vinci Robotic instruments in an infant's airway (from Rahbar et al⁶)

¹Director and Chairman, ²Medical Student (4th Year)

¹Department of Pediatric Otolaryngology – Head and Neck Surgery; Department of Otorhinolaryngology, University of Texas, Houston, Texas, USA

²McGovern Medical School, University of Texas, Houston Texas, USA

Corresponding Author: Soham Roy, Director and Chairman Department of Otorhinolaryngology, University of Texas Houston, Texas, USA, Phone: +17135006636, e-mail: Soham.Roy@uth.tmc.edu

of the da Vinci surgical robot (Intuitive Surgical, Sunnyvale, CA, USA), which is now the most widely used system. The da Vinci system is utilized most frequently in urological, gynecological, gastrointestinal, and cardiothoracic applications. In fact, over 70% of all procedures currently performed with the da Vinci system are either prostatectomy or hysterectomy. Robotic systems are used with less frequency in head and neck surgery, pediatric surgery, and general surgical oncology.³

Robotic surgery in the head and neck presents unique challenges because of the limited space in which a surgical robot can maneuver. Hockstein et al⁴ first established the feasibility of robotic surgery in the adult airway by successfully demonstrating the use of the da Vinci robot-assisted surgery in a mannequin model. Presently, TORS is FDA approved for head and neck tumor resection, and is commonly used for the treatment of early stage oropharyngeal and glottic tumors, which has been shown to reduce morbidity and improve functional outcomes.⁵

Although the confined space in transoral surgery presents a challenge in all robotic head and neck surgery, this problem is escalated by pediatric anatomy. The challenge of introducing robotic arms into the oral cavity is considered by many to be the primary impediment to the implementation of surgical robotics in the pediatric airway. Other challenges to the safe use of surgical robots for pediatric airway surgery include obtaining adequate means to administer airway anesthesia and obtaining sufficient exposure of the larynx to perform the surgery.⁶ Rahbar et al⁶ first established the technical feasibility of adapting robotic surgical techniques to the pediatric airway. In that study, two out of five patients successfully underwent correction of Type I and II laryngeal clefts using TORS, but three could not be completed. Although large series of robotic surgery for the pediatric airway are not yet available, currently published experiences suggest the possibility of improved outcomes with fewer complications. Some technical advantages are becoming apparent, including 3D visualization, increased freedom of instrument movement, and tremor filtration, which allows for gentler handling of delicate tissues.⁶ As experience with surgical robots increases and new technology is developed, performing pediatric robotic airway surgery may increase and lead to improved outcomes.

CURRENT DATA

Early experiences and outcomes in the field of robotic pediatric airway surgery are now being described. Thottam et al⁷ reported one of the first series examining the utility of TORS in base of tongue (BOT) reduction and lingual tonsillectomy for children with obstructive sleep apnea (OSA). Although TORS has been used

effectively for OSA in adults, the utility of this therapy in children has not been widely studied. In this series, nine patients with OSA due to BOT or lingual tonsillar hypertrophy were studied. These patients had previously been treated with adenotonsillectomy without resolution. Patients underwent BOT resection or lingual tonsillectomy using TORS and were evaluated using pre- and postoperative polysomnography measurements. The authors found that TORS for BOT resection and lingual tonsillectomy significantly reduced obstructive apnea hypopnea indices (OAHIs) and increased the average minimum oxygen saturation. When compared with outcomes for BOT resection and lingual tonsillectomy using endoscopic coblation, TORS was found to reduce OAHIs and increase average oxygen nadirs to a greater degree. The authors reported short hospital stays for their cohort, in addition to a low complication rate. These characteristics of TORS may lead to significant financial savings as well as improved outcomes for patients.

Importantly, this study demonstrated that OAHIs were reduced in the pediatric population to a degree comparable with adults, suggesting that TORS is a viable therapeutic option for both pediatric and adult populations with OSA. The primary complication encountered in this study was postoperative bleeding, which occurred in one out of nine patients. Although postoperative bleeding is acknowledged as a potential complication of pediatric robotic airway surgery, complication rates have not been fully determined secondary to small case numbers. The authors describe many intraoperative advantages in TORS procedures compared with endoscopic coblation when approaching the BOT and lingual tonsils in children. These include easier access to the operated area, a 3D view of the oropharyngeal cavity, and multiarticulating two-arm instrumentation. Compared with endoscopic coblation, TORS may offer improved outcomes, lower rates of complications, and intraoperative advantages including 3D endoscopic viewing, improved exposure, and increased freedom of motion. These data suggest that TORS is a viable therapeutic option for the treatment of OSA due to BOT or lingual tonsillar hypertrophy in the pediatric population.⁷

Leonardis et al² also reported the successful utilization of TORS in 16 children to perform lingual tonsillectomy. In addition to the intraoperative and functional outcomes reported by Thottam et al,⁷ this study suggests that a unique advantage of TORS is the "creation of a clean dissection plane, which provides unmatched exposure of the tongue base musculature."² Leonardis et al also analyzed a number of other parameters associated with the use of a surgical robot, including docking time (the time required to move the robot into position, connection of the robot arms to trocars, and installation of robotic

instruments and the camera) and estimated blood loss (EBL). They noted that docking time significantly decreased as the number of cases increased. It also showed that mean EBL was significantly reduced as a function of the number of cases performed. These two data suggest that experience with the surgical robot is a key parameter of success in pediatric robotic airway surgery.

Leonardis et al note that the cost of buying and maintaining a surgical robot is a significant obstacle to widespread implementation of robotic surgery. However, as the technology becomes more widely accepted, it is feasible that decreased operating room time, shorter hospital stays, lower complication rates, and lower readmission rates could offset the high costs.² It is likely that as experience with the robot and the number of cases performed at a given institution both increase, the net cost of robotic surgery could become more economically sustainable.

In addition to BOT resection and lingual tonsillectomy, surgeons have also reported early experiences with a wide variety of other interventions in the pediatric airway. Our group (Ferrell et al)⁵ reported a series of three pediatric airway cases utilizing robotic techniques in 2014. We described a patient with bilateral vocal fold immobility and posterior glottis stenosis; repair was initially attempted via TORS technique to perform a posterior cricoid split. Adequate visualization of the subglottis could not be achieved and the surgery was converted to an open approach. The next patient with a type II laryngeal cleft underwent successful correction of the cleft using TORS (Fig. 2). The third patient had a posterior cordectomy and arytenoidectomy using TORS for idiopathic bilateral vocal fold paralysis. The postoperative course was complicated by oral tongue edema, decreased oral intake, and suspected aspiration.⁵ In addition to these cases, Kayhan et al⁸ have reported the successful use of TORS to resect a thyroglossal duct cyst in an infant, who tolerated the procedure without complication. The authors of these studies reported that

TORS provided improved endoscopic visualization, superior instrument control, tremor reduction, and effective instrument manipulation. In addition, the minimally invasive nature of TORS avoids the external scarring inherent in open cases, may reduce perioperative morbidity, and thus expedite recovery.⁵

Hockstein et al⁴ proposed that widespread adoption of robotic surgery in the pediatric airway would necessitate miniaturization of the apparatus and attachments. To address this issue, some companies are developing robotic systems specifically designed for use in head and neck surgery. One such machine is the Flex Robotic System (MedRobotics, Raynham, MA, USA). The Flex system has been successfully used for airway procedures in Europe. An assessment of this technology stated that it provides increased access and vision compared with other robotic systems used for surgery in the larynx.⁹ The FDA approval granted in 2015 in the United States was followed by a cadaver study showing the feasibility of epiglottectomy, BOT resection, and vocal cord excision. The Flex system provides a flexible endoscopic camera that can work its way around corners in the oropharynx, hypopharynx and larynx, allowing better exposure of anatomy that is traditionally difficult to access, and providing access for flexible surgical instruments (Fig. 3).¹⁰

As technology continues to advance, the possible applications of pediatric robotic airway surgery are broadening. Faust and Rahbar¹¹ have published work exploring the possible employment of TORS for pediatric laryngotracheal reconstruction. Newer adaptations of robotic surgery include remote robotic surgery using telemedicine. The potential applications of remotely performed robotic surgery have historically been of particular interest to the US Army and National Aeronautics and Space Administration as a means for a surgeon to remotely attend to a soldier or astronaut without being in their immediate physical environment.¹² One example of this technology at work in the context

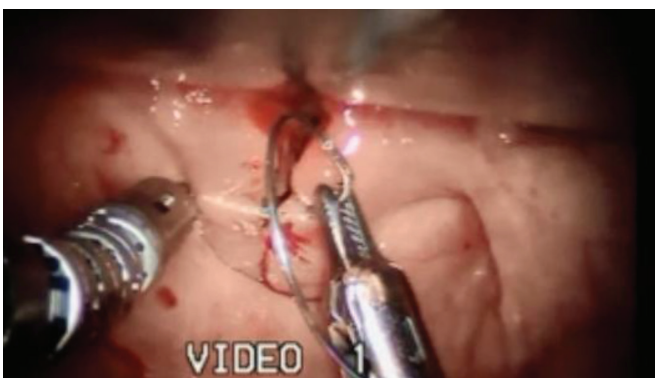


Fig. 2: Robotic laryngeal cleft closure

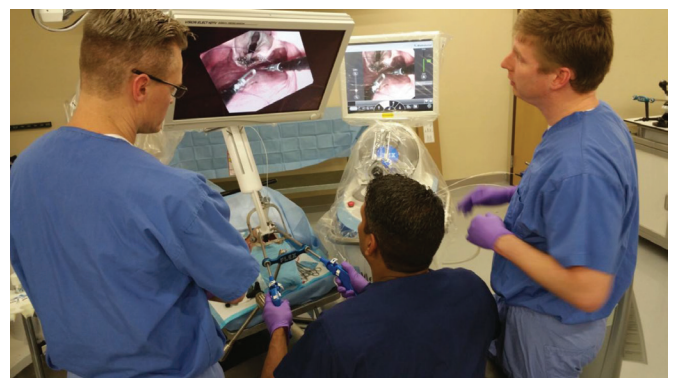

Fig. 3: The senior author testing the Flex robotic system

of robotic airway surgery was demonstrated by Tighe et al,¹³ who successfully performed oral as well as nasal intubation of a mannequin from a remote location using a surgical robot.

CONCLUSION

Multiple studies have established the technical feasibility and advantages of robotic surgery in the pediatric airway. Transoral robotic surgery boasts of 3D vision, increased instrument maneuverability, and tremor filtration. In addition, TORS has the potential to decrease operating room time, shorten hospital stays, reduce complications, and lower readmission rates. However, current robotic platforms may be too large and cumbersome for the pediatric airway, and deployment of the systems can be expensive, time consuming, and involve a considerable learning curve. Furthermore, the lack of haptic feedback and lack of instruments developed specifically for the intricacy of the pediatric airway may be detractors. Given the potential advantages of utilizing TORS in the pediatric airway, it is expected that the employment of surgical robots for this purpose will increase in the future. It is clear that large-scale studies yielding more data as well as further technological advancements must precede the widespread dissemination and practice of pediatric robotic airway surgery.

REFERENCES

1. Weinstein, GS.; O'Malley, BW Jr. Transoral robotic surgery (TORS). San Diego: Plural Publications; 2012.
2. Leonardis RL, Duvvuri U, Mehta D. Transoral robotic-assisted lingual tonsillectomy in the pediatric population. *JAMA Otolaryngol Head Neck Surg* 2013 Oct;139(10):1032-1036.
3. Leung T, Vyas D. Robotic Surgery: applications. *Am J Robot Surg* 2014 Jun 1;1(1):1-64.
4. Hockstein NG, Nolan JP, O'Malley BW Jr, Woo YJ. Robotic microlaryngeal surgery: a technical feasibility study using the daVinci surgical robot and an airway mannequin. *Laryngoscope* 2005 May;115(5):780-785.
5. Ferrell JK, Roy S, Karni RJ, Yuksel S. Applications for transoral robotic surgery in the pediatric airway. *Laryngoscope* 2014 Nov;124(11):2630-2635.
6. Rahbar R, Ferrari LR, Borer JG, Peters CA. Robotic surgery in the pediatric airway: application and safety. *Arch Otolaryngol Head Neck Surg* 2007 Jan;133(1):46-50.
7. Thottam PJ, Govil N, Duvvuri U, Mehta D. Transoral robotic surgery for sleep apnea in children: is it effective? *Int J Pediatr Otorhinolaryngol* 2015 Dec;79(12):2234-2237.
8. Kayhan FT, Kaya KH, Koc AK, Altintas A, Erdur O. Transoral surgery for an infant thyroglossal duct cyst. *Int J Pediatr Otorhinolaryngol* 2013 Sep;77(9):1620-1623.
9. Johnson PJ, Rivera Serrano CM, Castro M, Kuenzler R, Choset H, Tully S, Duvvuri U. Demonstration of transoral surgery in cadaveric specimens with the medrobotics flex system. *Laryngoscope* 2013 May;123(5):1168-1172.
10. Roy S, Karni RJ. Feasibility of a novel robotic platform for laryngeal surgery. *Otolaryngol Head Neck Surg* 2015 Sep;153:82.
11. Faust RA, Rahbar R. Robotic surgical technique for pediatric laryngotracheal reconstruction. *Otolaryngol Clin North Am* 2008 Oct;41(5):1045-1051, xi.
12. Lanfranco AR, Castellanos AE, Desai JP, Meyers WC. Robotic surgery: a current perspective. *Ann Surg* 2004 Jan;239(1):14-21.
13. Tighe PJ, Badiyan SJ, Luria I, Lampotang S, Parekattil S. Robot-assisted airway support: a simulated case. *Anesth Analg* 2010 Oct;111(4):929-931.