

Selecting Different Surgical Approaches for Hypopharyngeal Obstruction

Chu Qin PHUA¹, Shaun Ray Han LOH², Song Tar TOH³

ABSTRACT

Introduction: Surgery for obstructive sleep apnea (OSA) has evolved significantly over the last few decades owing to lessons learned from prior failures and increased understanding of this condition. Analysis of single-level palatal surgery failures and the advent of sleep endoscopy showed the presence of a concomitant hypopharyngeal obstruction, highlighting the importance of hypopharyngeal obstruction in the treatment of OSA.

Objective: This article aims to delineate the concepts behind optimal patient selection for hypopharyngeal OSA surgery.

Results: Understanding the various factors contributing to hypopharyngeal obstruction allows the treating surgeon to build a framework in the thought process. This allows customization in selecting proper surgical techniques for individual patients in the setting of treating this multifactorial condition. These concepts include understanding the significance of hypopharyngeal obstruction, the concept of volume reduction versus tension enhancement in upper airway surgery, synchronization of major airway dilator with respiration during sleep, the notion of multilevel surgery and significance of holistic management in OSA. It is also important to understand multiple surgeries or different types of surgery may be applicable at the different timeline, for the same patients.

Optimal treatment outcome relies on accurate assessment. Assessment methods of particular relevance to hypopharyngeal surgery for OSA include drug-induced sleep endoscopy, Friedman Tongue Position and tongue base lymphoid tissue grading. Types of hypopharyngeal surgery, their indication and efficacy are also discussed in this article.

Conclusion: Hypopharyngeal obstruction is prevalent, and its presence is associated with increased OSA severity. In the context of hypopharyngeal surgery for OSA, the key achieving optimal outcome is integration of targeted treatment, clinical expertise, patient preference, and understanding potential positive and negative predictive clinical findings.

Keywords: Hypopharyngeal obstruction, Hypopharyngeal surgery, Patient selection, Surgical approach, Obstructive sleep apnea.

International Journal of Head and Neck Surgery (2019): 10.5005/jp-journals-10001-1375

Aim

Surgery for obstructive sleep apnea has evolved significantly over the last few decades. This article aims to delineate the concepts behind optimal patient selection for hypopharyngeal OSA surgery, as well as to briefly discuss the various surgical approaches for hypopharyngeal obstruction, with the objective of ensuring best patient outcomes.

BACKGROUND

Since the first description of uvulopalatopharyngoplasty (UPPP) by Fujita in 1981,¹ surgical treatment of the obstructive sleep apnea (OSA) has expanded from a single level palatal surgery to a tailored treatment of other nonpalatal sites of airway obstruction. This stems from lessons learned from prior surgical failures and increasing awareness that upper airway collapse is often multilevel.²⁻⁴ Sher et al. demonstrated that failure of single-level palatal surgery was largely attributed to the presence of a concomitant hypopharyngeal obstruction,⁵ highlighting the importance of hypopharyngeal obstruction in the treatment of OSA. Powell and Riley have been the very first surgeons to understand the complexity of OSA and incorporated multilevel surgical techniques in their treatment protocol.²

The decision for treatment of a hypopharyngeal obstruction in OSA is complex owing to the intricate interaction of the tongue, lateral pharyngeal wall, aryepiglottic folds, and the epiglottic collapse. Multiple surgical options exist for treatment of hypopharyngeal obstruction. Identifying the obstruction site and mechanism and subsequently matching it with the adequate

¹Department of Otolaryngology, Sengkang General Hospital, Singapore

²Department of Otolaryngology, Singapore General Hospital, Singapore

³Department of Otolaryngology, Singapore General Hospital; SingHealth Duke-NUS Sleep Centre; National University of Singapore; Yong Loo Lin School of Medicine & Duke-NUS Medical School, Singapore

Corresponding Author: Song Tar TOH, Department of Otolaryngology, Singapore General Hospital; SingHealth Duke-NUS Sleep Centre; National University of Singapore; Yong Loo Lin School of Medicine & Duke-NUS Medical School, Singapore, e-mail: toh.song.tar@singhealth.com.sg

How to cite this article: PHUA CQ, LOH SRH, TOH ST. Selecting Different Surgical Approaches for Hypopharyngeal Obstruction. *Int J Head Neck Surg* 2019;10(3):67-76.

Source of support: Nil

Conflict of interest: None

corrective procedure is of utmost importance in ensuring the best surgical outcomes.

Basic Concepts in Hypopharyngeal Surgery

Several concepts form our basic paradigm in the surgical treatment of a hypopharyngeal obstruction in OSA patients. Understanding these concepts builds a framework in the thought process of customizing the treatment decisions to individual patients in the setting of multiple variables.

Table 1: Surgical procedures for hypopharyngeal obstruction

	<i>Soft tissue volume reduction</i>	<i>Tension enhancement</i>
Tongue	Midline glossectomy Radiofrequency ablation to tongue base	Genioplasty Genioglossus advancement Hypoglossal nerve stimulation
Lingual tonsil	• Lingual tonsillectomy • Transoral robotic tongue base reduction (TORS) Coblation assisted	
Lateral pharyngeal wall		Maxillomandibular advancement Hyoid suspension
Epiglottis	Partial epiglottectomy	Hyoepiglottoplasty Aryepiglottoplasty

Significance of Hypopharyngeal Obstruction

In the context of sleep surgery, hypopharyngeal collapse is broadly accepted as an area encompassing tongue base, lingual tonsil, epiglottis, aryepiglottic fold and hypopharyngeal wall.⁶ The significance of hypopharyngeal obstruction was recognized early back in the 1990s by Powell and Riley from Stanford University, with the incorporation of surgical techniques to address hypopharyngeal obstruction in their dynamic OSA surgery protocol when they published their result in 1993.²

Hypopharyngeal obstruction is common in OSA patients, occurring in 38.7% of patients and tongue base obstruction in 46.6%, according to a large study by Vroegop et al.³ In Asian patients, the prevalence of hypopharyngeal obstruction and tongue base obstruction is at 52.5% and 46.2%.⁴

Hypopharyngeal obstruction is associated with increased OSA severity and obesity which predisposes to hypopharyngeal obstruction.^{3,4} Surgeons also need to be aware of hypopharynx's role in respiration, speech, and swallowing, which has to be taken into consideration when surgery is performed. In particular, care should be taken to manage and avoid postoperative edema or hemorrhage in the hypopharynx which can threaten the patency of the airway.

Volume Reduction versus Static Tension Enhancement versus Dynamic Airway Enhancement

The concept of upper airway surgery revolves around normalizing the airway in form and function by altering abnormal anatomy and pathophysiology causing the narrowed airway and can be achieved by:

- Reduction of soft tissue volume resulting in an increase of upper airway passage volume
- Modification of tension around the upper airway, as well as
- Dynamic airway enhancement with hypoglossal nerve pacing to tone up tongue muscle, synchronize airway opening and to resist obstructive negative pressure as a result of inspiration.

Volumetric reduction surgery is more suited for correction of soft tissue excess or hypertrophy, such as in bulky tongue base or lymphoid tissue hypertrophy. Conversely, tension enhancement surgery aims to reduce overall tissue laxity such as those of lateral pharyngeal wall (constrictor muscles), those with floppy epiglottis and/or a collapsing tongue base not attributable to excess volume. Indications for dynamic airway enhancement using hypoglossal nerve stimulation will be delineated below.

For surgical modification of the hypopharyngeal airway, various surgical procedures are discussed below to correct the collapse at

the tongue, lingual tonsil, lateral pharyngeal wall, and the epiglottis. Table 1 summarizes the different surgical procedures available to treat hypopharyngeal obstruction.

Multilevel Surgery

Whilst this paper's focus is on the selection of surgical correction for hypopharyngeal obstruction in OSA to improve surgical outcomes,⁷ it is important to know that efficacy of surgical treatment lies in localizing the level of anatomic obstructions and providing adequate corrective treatment. It is crucial for sleep surgeons to consider combination treatment of other anatomic obstructions such as nose, palate, and oropharynx if such obstructions coexist. Indeed, multilevel surgery has been shown to improve patient outcomes, with a surgical success rate of up to 66.4%,⁸ compared to the conventional single-level UPPP at 40%.⁵

Holistic Management

Apart from considering surgical treatment, sleep surgeons must equip themselves with various other strategies in their armamentarium to provide holistic care to the patient. These treatment strategies can be used in combination with surgical treatment, or as an alternative or salvage therapy. Various other adjunct treatment modalities and lifestyle modifications can be utilized in the treatment of OSA, including:

- Myofunctional therapy
- Weight management and maintenance
- Sleep hygiene and lifestyle modification
- Understanding various OSA phenotypes.

Myofunctional therapy can be useful for hypopharyngeal obstruction. It represents a set of exercises for the lip, tongue, soft palate and lateral pharyngeal wall, aimed at training the upper airway dilator muscles to maintain the patency of the upper airway during sleep.⁹ Systematic review and meta-analysis by Camacho et al. in 2015 demonstrated a statistically significant reduction of AHI from a mean of 24.5 to 12.3 per hour ($p < 0.0001$).¹⁰ Also, improvement of lowest oxygen saturation, snoring and sleepiness scale has also been shown.¹⁰

Given that obesity predisposes to hypopharyngeal obstruction,^{3,4} weight reduction can lead to improvement of hypopharyngeal collapse. OSA patients have been shown to have increased parapharyngeal fat pad volumes¹¹, as well as tongue fat deposition.¹² Weight loss strategies including diet modification, entry into weight loss program, and bariatric surgery, can lead to significant weight loss and reduction in AHI. Peppard et al. demonstrated that weight reduction of 10% can lead to a 20% reduction of AHI.¹³

Optimizing sleep hygiene is also essential in improving sleep quality and overall quality of life in OSA patients. Sleep hygiene education involves pinpointing causation of sleep disturbance, correction of misconceptions or preformed ideas on sleep, ensuring optimal daily habit and sleep environment to improve the quality of sleep.

Also, novel concepts on pathophysiology have shed light on the complex causation of OSA. It is now known that OSA patients have individual phenotypes by which their upper airway obstruction occurs due to a complex interplay between the upper airway anatomy, upper airway dilator muscle function, individual arousal threshold, stability of ventilatory loop gain and nocturnal rostral fluid shift.¹⁴ Whilst patients with abnormal upper airway anatomy can benefit from surgical modification, patients with other traits such as low arousal threshold can benefit from sedatives to improve sleep quality and reduce AHI. Patients with ventilatory control stability can improve with oxygen therapy and acetazolamide, whereas patients with overnight rostral fluid shift causing OSA can benefit from diuretics, compression stockings, and head elevation.¹⁴ This area is still under intense research and hopefully, future results can help surgeons better select patients.

Surgical Goal

Before performing hypopharyngeal surgery for OSA, it is important for the surgeon to ascertain and communicate the surgical goal with the patient and what surgery can realistically achieve. Surgical goals to be considered include

- To facilitate CPAP usage
- To improve compliance
- As a primary treatment after CPAP failure. The following points have to be taken into account
 - Patients' aim for surgery: Snoring reduction, AHI severity reduction, Bed partners' sleep, daytime functioning
 - Reducing long-term morbidity and mortality risk associated with OSA, with a reduction in disease severity, even in the absence of a complete cure.

Depending on the surgical goals, consideration may be given to performing minimally invasive surgery or staged surgery for facilitation of CPAP usage or reduction of snoring, with the deliberation of reducing risks of surgical morbidities.

REVIEW RESULTS

Selecting Patient for Hypopharyngeal Surgery

Careful evaluation and selecting the right patient for the right surgery will ensure better success. Various static and dynamic evaluation methods are available for assessment of OSA obstruction sites. These include imaging studies such as lateral cephalograph, CT scan, MRI scan, fluoroscopy, as well as other assessment methods such as clinical inspection of palatine and lingual tonsil size, Friedman tongue position, assessment of craniofacial structure deficits, flexible nasoendoscopy and drug-induced sleep endoscopy. The authors use the following methods to assess for hypopharyngeal obstruction:

- Drug-induced sleep endoscopy
- Friedman tongue position
- Tongue base lymphoid tissue.

Drug-induced Sleep Endoscopy

Method: Drug-induced sleep endoscopy (DISE) is an upper airway endoscopic evaluation method which allows assessment of upper

airway collapse under sedation. DISE is a diagnostic tool indicated in patients with snoring or OSA, in whom non-CPAP therapy is being considered. Sedatives such as midazolam, propofol, diazepam, and dexmedetomidine can be used.¹⁵ Anticholinergics can be considered to reduce upper airway secretions to aid better assessment.¹⁵ However, use of nasal local anesthesia and decongestant, whilst may ease scope insertion, could potentially alter nasal resistance and upper airway dynamics.¹⁶ The depth of sedation can be measured with bispectral index (BIS) at target values between 50 and 70.16. The European position paper for 2014 suggested observation of at least 2 or more cycles (progression from snoring to obstruction or oxygen desaturation to the resumption of breathing) for each segment of upper airway.¹⁶

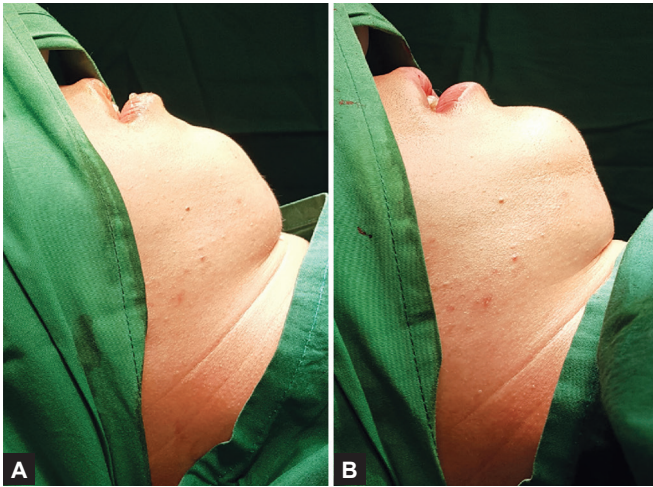
Grading: There are two prevalent systems that are used for the grading of DISE, which includes the VOTE system proposed by Kezirian et al.¹⁷ and the NOHL system by Vicini et al.¹⁸ as shown below. The key to reporting and grading of the DISE findings is that it should include levels of collapse, the pattern of collapse (lateral, anteroposterior or concentric), as well as the degree of obstruction and vibration at the nose, retropalatal area, retroglottal area, lateral wall of the entire airway.

Evidence and relevance: Current gold standard for evaluation for OSA is DISE. DISE has been shown to impact the selection of surgical approaches because of abnormal anatomy seen.^{19,20} Some studies have also shown that DISE improves postoperative AHI compared to conventional assessment.²⁰ In a systematic review by Certal et al., it is found that DISE has a particular impact on changing the recommendations concerning hypopharyngeal or laryngeal obstruction.¹⁹ It is important to note that the airway obstruction is dynamic and the classifications system may not fully capture the dynamic airway obstructions seen and the authors use descriptive terms to describe the airway obstruction seen.

In patients with retrognathia (Fig. 1), the authors use jaw thrust maneuver to assess whether mandibular advancement splint, genioglossus advancement, genioplasty or maxillomandibular advancement will open the airway at the hypopharyngeal site. Sliding genioplasty maybe more suited in patients with retrognathia as it also improves aesthetics (Fig. 2). In patients with a normal mandible, ageniotubercle advancement maybe better. The presence of an epiglottic obstruction (Fig. 3) during sleep endoscopy will necessitate a partial epiglottidectomy (Fig. 4).

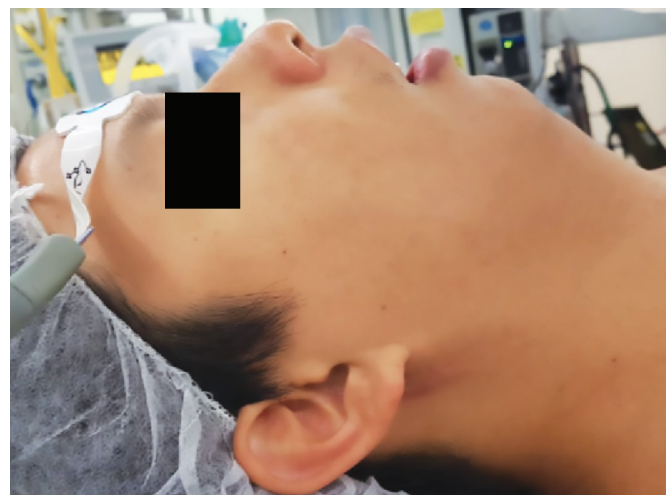

Fig. 1: Patient with retrognathia



Figs 2A and B: Preoperative and postoperative picture of patient who underwent sliding genioplasty

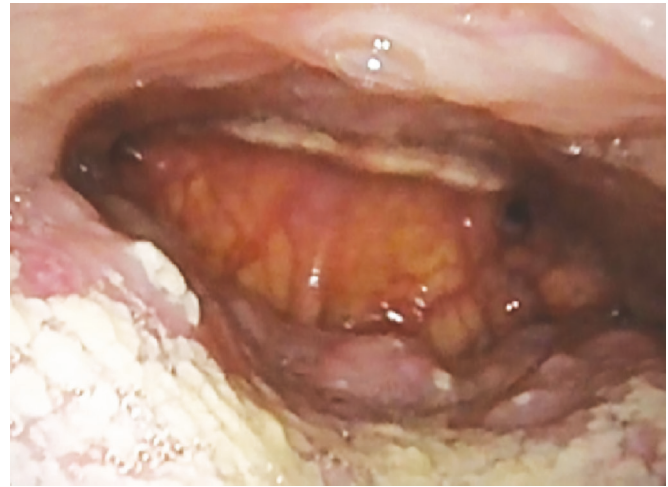
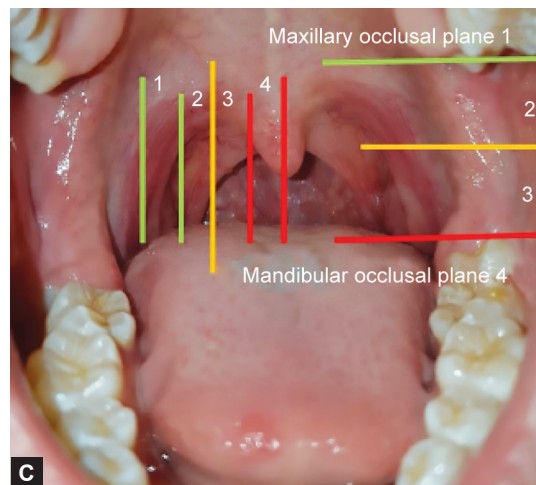
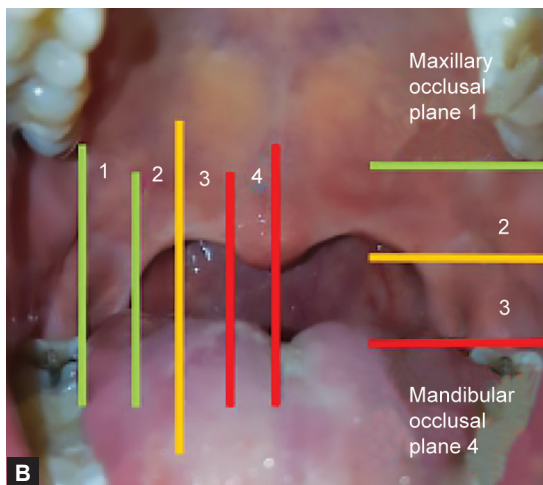
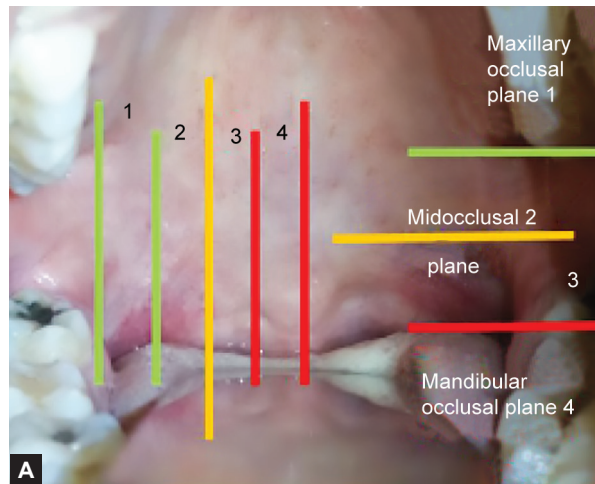


Fig. 3: Flexible nasoendoscopic picture demonstrating epiglottic obstruction during sleep endoscopy



Figs 4A to C: (A) Palate of an OSA patient below midocclusal plane; (B) Palate of OSA patient after surgery, showing palate height above midocclusal plane; (C) Palate of a non-OSA patient showing palate above midocclusal plane

Friedman Tongue Position

Method: Friedman tongue position is a grading system that grades the tongue position in relation to tonsil, uvula, soft and hard palate (Table 2).²¹ The patient should be asked to avoid sticking their

tongue out, and instead to have it inside the mouth in its natural and neutral position.²¹ The rationale behind this is that the resting tongue position during sleep is not held in a protruded position. As described by Friedman et al., the patient should be asked to open

Table 2: Friedman tongue position

<i>Friedman tongue position (FTP) stage</i>	<i>Description</i>
FTP I	Entire tonsils/tonsillar pillar, uvula, soft palate and hard palate are visualized.
FTP IIa	Partial view of tonsils, but entire uvula, soft and hard palate are visualized.
FTP IIb	Tonsil and uvula are not seen. Only uvula base, soft palate, and hard palate are seen.
FTP III	Tonsils and uvula are not seen, but soft palate and hard palate are seen.
FTP IV	Only hard palate is visualized.

Table 3: Lingual tonsil grading

<i>Lingual tonsil grading</i>	<i>Description</i>
Grade 0	Complete absence of lymphoid tissue on tongue base
Grade 1	Lymphoid tissue scattered over tongue base
Grade 2	Lymphoid tissue covering entire tongue base but with limited vertical thickness
Grade 3	Lymphoid tissue covering entire tongue base With a raised thickness of approximately 5–10 mm Between 25–27% of epiglottis height
Grade 4	Lymphoid tissue 1 cm or more in thickness Vertical height rising above the tip of the epiglottis.

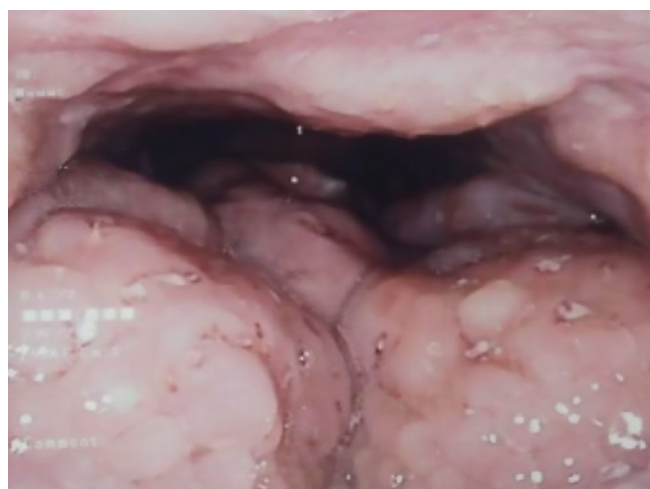
his or mouth repeatedly for at least five times, without protruding their tongue, so that the most accurate level of tongue position can be assessed.²¹

Evidence and relevance: Friedman tongue position provides an indication of the degree of tongue base obstruction as well as the size of the tongue. Friedman tongue position grading has been shown to be inversely correlated with posterior airway space as measured on cone beam CT (CBCT) scan, in a study done by Harvey et al.²² The study showed that the higher the Friedman tongue position grading (III, IV), the narrower the posterior airway space.²² Used in conjunction with findings from other evaluation methods, FTP can be used to guide surgical management of tongue base obstruction. The presence of scalloping is a sign of macroglossia or relative macroglossia where the tongue is big relative to the small mandible. Consideration can be given to performing various procedures ranging from radiofrequency ablation of the tongue base, coblation tongue channeling, coblation-assisted midline glossectomy, genioglossus advancement, hypoglossal nerve stimulation and maxillomandibular advancement to as a treatment for tongue base obstruction.

It is important not to confuse Friedman tongue position with the palate length. These two are interrelated but mutually exclusive. A well reconstructed soft palatal will bring the lowest point of soft palate above the mid-occlusal plane in the mouth opening position, from one that is below the mid-occlusal plane or below the mandibular occlusal plane in mouth opening position, normalizing it. Tongue volume reduction surgery should bring the tongue down to an FTP 1 position.

Lingual Tonsil Hypertrophy Assessment

Method: Lingual tonsil hypertrophy can cause significant hypopharyngeal collapse and increase the severity of OSA. Evaluation of lingual tonsil is performed with flexible nasoendoscopy either in the patient's awake state or during drug-induced sleep endoscopy (DISE). Friedman et al. recommended that the lingual tonsils be assessed in an awake patient with the tongue in multiple positions.²³ For most patients, lingual tonsils are best seen with the tongue protruded.²³ However, multiple views with the tongue in a different position would provide the surgeon a better perception of


Fig. 5: Grade IV lingual tonsil hypertrophy

the lingual tonsils height in relation to surrounding hypopharyngeal airway (Table 3). Sleep endoscopy is important to assess if the lingual tonsils obstruct the airway.

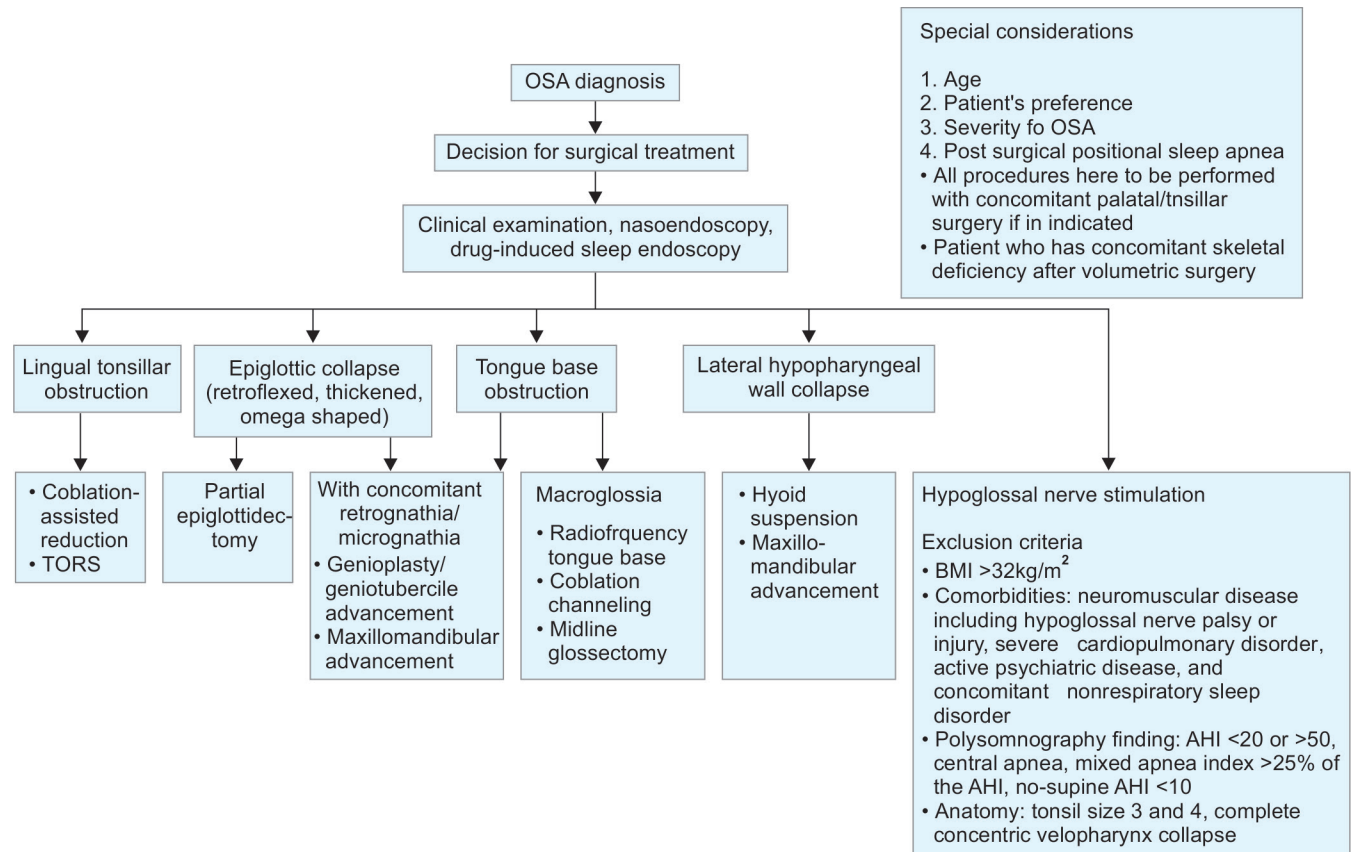
Evidence and Relevance

The standardized lingual tonsil hypertrophy assessment and grading as described by Friedman et al.²⁴ demonstrated good inter-examiner agreement, making it a useful standardized tool for evaluation and communication.²⁴ Lingual tonsil obstruction (Fig. 5) can be treated with lingual tonsil reduction either via transoral robotic surgery or coblator-assisted reduction.

Types of Hypopharyngeal Surgeries, Indications, and Efficacy

Hypopharyngeal surgeries have been shown to improve outcomes in OSA. 7.7 Selecting the appropriate surgical intervention holds the key to the successful outcome. Flowchart 1 demonstrates the decision making and treatment algorithm of the authors. The individual procedures used for the treatment of hypopharyngeal obstruction (as shown in Table 1) are discussed below, with specific attention to each of their indication and efficacy.

Flowchart 1: Selecting hypopharyngeal surgeries — A guide



Coblator-assisted Lingual Tonsil Reduction

Coblator-assisted lingual tonsil reduction is indicated for lingual tonsil hypertrophy causing obstruction. Coblation lingual tonsillectomy requires nasotracheal intubation, a retraction stitch at the anterior tongue, a bite block to keep the mouth open and then a 70° sinus endoscope to provide direct visualization of the lingual tonsil. The coblation technology is applied via a malleable coblation wand, where the lingual tonsils are ablated and reduced under direct visualization. The coblation technology involves the creation of a plasma field with bipolar radiofrequency that leads to soft tissue dissolution.

Coblation lingual tonsillectomy in the select group with lingual tonsillar hypertrophy demonstrated a statistically significant reduction in AHI.²⁵ Postoperative complications are infrequent, ranging 2–14%.^{25–27} However, they can be potentially severe, causing hemorrhage and airway compromise requiring reintubation.^{25–27} It is also important to note that these reported successes and complication rates are reports from small series.

Transoral Robotic Surgery Resection of Lingual Tonsil

Since the first transoral robotic surgery (TORS) was performed for OSA in 2008, there has been increased utilization of TORS as part of the multilevel approach in OSA surgery. In the context of OSA, TORS can be used to address the anatomically difficult to reach the area of lingual tonsil, tongue base muscle hypertrophy as well as an obstructive epiglottis. Transoral access afforded by TORS avoids disfiguring external scars. The robotic instruments which allow 360 degrees rotation gives freedom of motion and better access to the traditionally difficult to access area of the oropharynx.

Recent systematic review and meta-analysis showed that TORS base of tongue reduction led to statistically significant reduction of AHI, improvement in lowest oxygen saturation, snoring visual analog scale and Epworth Sleepiness Scale.²⁸ In the meta-analysis by Rangabashyam et al. in 2016 of 451 adult patients, pooled analysis showed statistically significant improvements in AHI, LSAT, and ESS after surgery by 26.83/hour, 5.28% and 8.03. The surgical cure was 23.8% and 66.7% of patients achieved surgical success.²⁸ There were no reported deaths or serious complications related to the use of robotic equipment. Major complication rate was 6.9%, and minor complication rate was 30.0%. Major complications reported included major bleeding (2.9%), severe odynophagia with dehydration (3.3%), and oropharyngeal stenosis (0.7%).²⁸ Minor complications included transient bleeding (0.5%), transient dysphagia (3.8%), and dysgeusia (6.6%).²⁸ Miller et al. reported similar findings in AHI, ESS and VAS score.²⁹

In a large multicentre retrospective analysis evaluating complications of TORS for OSA, reported results showed minimal long-term morbidity.³⁰ In the data collected from 7 centers across Europe and the United States showed complications in 20.5% of patients, commonest being transient hypogeusia and bleeding.³⁰ Other complications include transient pharyngeal edema and pharyngeal stenosis.³⁰

Partial Epiglottidectomy

Presence of epiglottic collapse seen during DISE suggests the need for partial epiglottidectomy. A recent systematic review by Torre et al. showed that epiglottis collapse in OSA is more prevalent than previously reported.³¹ Surgery plays an important role as an

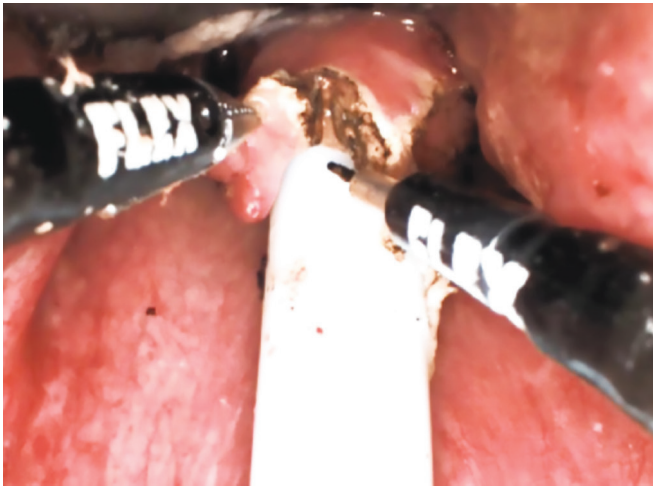


Fig. 6: Flex robotic partial epiglottectomy

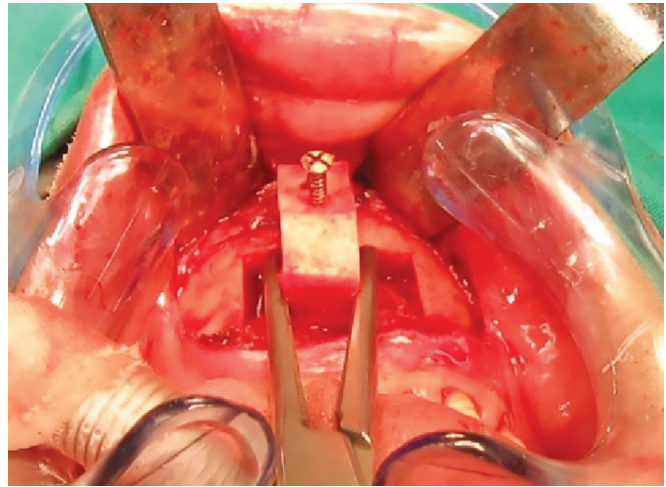


Fig. 7: Geniotubercle advancement

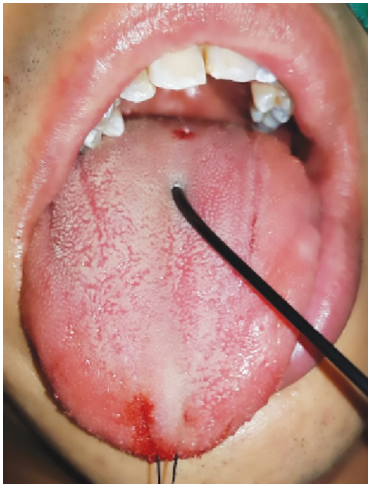

Fig. 8: Coblation tongue channelling

intervention strategy as other treatment modalities such as CPAP can sometimes worsen upper airway collapse in pushing the lax epiglottis against the laryngeal inlet.³¹ Partial epiglottidectomy can be performed via direct laryngoscopy approach or the TORS approach. The upper 1/3 of epiglottis can be resected via diathermy or laser, leaving the lower 2/3 for laryngeal inlet closure during swallowing to prevent aspiration (Fig. 6).

Catalfumo et al. demonstrated that partial epiglottidectomy when combined with other procedures, can increase OSA cure rate from 50 to 65%.³² In our senior author's series, transoral robotic partial epiglottidectomy, performed in combination with palatal surgery and tongue base reduction led to cure (AHI <5) in 7 of 20 patients (35%), surgical success (AHI <20 or reduction >50%) in 11 of 20 (55%).³³

Geniotubercle Advancement, Genioplasty

Genial tubercle advancement or genioglossus advancement is a procedure that involves the movement of genial tubercle with its attached genioglossus muscle anteriorly, via an osteotomy within the anterior aspect of the mandible (Fig. 7). Genioplasty is a slight variation where genial tubercle is advanced via a horizontal sliding osteotomy. Both procedures move the genioglossus muscle anteriorly with a resultant increase in the posterior airway

space. It is indicated in patients with tongue base obstruction, with concomitant retrognathia or micrognathia. In a recent systematic review and meta-analysis by Song et al. showed that both genioplasty and geniotubercle advancement procedures result in statistically significant reduction in AHI and improvement of lowest oxygen saturation.³⁴ In the review, genioplasty reduces AHI by up to 43.8%. Geniotubercle advancement was found to reduce AHI by 45.7%.³⁴

Radiofrequency Ablation or Coblation Channeling of the Tongue Base

Radiofrequency ablation of tongue base represents a useful surgical strategy in the reduction of tongue base volume for patients with macroglossia. Radio frequency ablation of tongue base can be performed with monopolar or bipolar radiofrequency, or with the coblation technology which is a bipolar radiofrequency applied through an ionic fluid such as saline, creating a plasma field that ablates surrounding tissue (Fig. 8).

In a series of patient who underwent a combination of coblation tongue channelling and modified uvulopalatopharyngoplasty, Mackay et al. demonstrated that patients with Friedman stage III (Friedman tongue position III and IV, tonsil sizes 0, 1 or 2, BMI <40) showed more encouraging response, with 71% surgical success,³⁵ compared the reported 8% surgical success in Friedman stage III patients who underwent UPPP alone as shown by Friedman et al.²¹ In a randomized trial by Woodson et al., which compared radiofrequency ablation of tongue and soft palate to sham surgery, patients who underwent surgery demonstrated better AHI reduction and improved quality of life measurements.³⁶ The effect of combined radiofrequency ablation of tongue and palate was shown to be sustained at a follow up of 23 months, with a sustained reduction in AHI and daytime sleepiness.³⁷

Maxillomandibular Advancement

Maxillomandibular advancement (MMA) is a multilevel skeletal surgery that expands the facial skeletal framework, creating an anterior advancement of soft tissues attached to it, including that of the soft palate, tongue base, and suprahyoid muscles. This leads to a resultant effect of widened retropalatal, retrolingual and hypopharyngeal airway. Although often viewed as invasive, maxillomandibular advancement represents one of the most

effective surgical methods in the modification of OSA airway. It is indicated for tongue base and/or lateral hypopharyngeal wall obstruction with concomitant maxillary/mandibular skeletal deficiency. It often serves as a surgical option for patients who are refractory to other surgical interventions.

In a meta-analysis which includes 45 studies with 518 patients, MMA demonstrated a significant reduction of AHI (reduction of 47.8 events/hour) and RDI (reduction of 44.4 events/hour).³⁸ The meta-analysis also showed that MMA led to an improvement with the lowest oxygen saturation from 80 to 87% and reduction of Epworth Sleepiness Score from 13.5 to 3.2.³⁸ Rates of surgical success were 85.5% (289 of 518 patients).³⁸

Hyoid Suspension

Hyoid suspension procedure is indicated for the treatment of hypopharyngeal wall collapse. It can be performed via suspension to the mandibular periosteum (hyomandibular suspension) as described by Riley et al.³⁹ or suspension toward thyroid cartilage (thyrohyoidopexy). Theoretically, this creates an anterior vector and movement of the hyoid bone, leading to the tension of the laryngeal pharyngeal wall. However, it should be noted that awake MRI study in patients who had hyoid suspension did not show enlargement of the hypopharyngeal airway.⁴⁰

Hyoid suspension performed as part of multilevel surgery for OSA showed significant AHI reduction (from 38.3 to 18.9) compared to those without hyoid suspension (from 28.6 to 21.7).⁴¹ Similar results were shown by Verse et al. where the addition of hyoid suspension led to significant AHI reduction compared to those without.⁴²

Hyoid Expansion

The OSA patients have smaller hyoid and hence smaller airway size compared to normal individuals, and severity of OSA is related to the area within the hyoid bone.⁴³ In a small case series of hyoid expansion⁴⁴ and a cadaveric study,⁴⁵ studying hyoid expansion showed increase airway dimension. Future studies may be needed to prove their clinical use.

Hypoglossal Nerve Stimulation

Hypoglossal nerve stimulation involves the use of a pacemaker-like implanted device to stimulate hypoglossal nerve which leads to protrusion of genioglossus muscle, which is the predominant dilator muscle of the upper airway. This therapy modality uses neurostimulation to target muscle inactivation. Hypoglossal nerve stimulation leads to widening of the retroglossal airway, as well as retropalatal airway via palatoglossus coupling of the soft palate to tongue base.⁴⁶ At present, although approved by FDA, hypoglossal nerve stimulation therapy still has stringent exclusion criteria as shown in Flowchart 1. Drug-induced sleep endoscopy emerged as an important evaluation tool in the assessment of the patient for hypoglossal nerve stimulation. In particular, the presence of complete concentric velopharynx collapses is found to be unfavorable.

Initial trials and subsequent 36-month follow-up showed that hypoglossal nerve stimulation is effective in the treatment of moderate-to-severe OSA.^{47,48} At 12 months following hypoglossal nerve stimulation, surgical success was 66% (83 out of 126 patients).⁴⁷ This is sustained at the 36-month follow-up with the surgical success of 74%.⁴⁸ At 48 months of follow-up, the same cohort of patients showed sustained improvement in Epworth Sleepiness Score, functional outcome measures and snoring.⁴⁹

Special Considerations

In formulating a surgical plan, apart from anatomical considerations, attention should be paid to other factors such as the age of the patient, severity of OSA and patient's preferences. In the post-surgery state, it is important to be aware of the potential presence of post-surgery positional OSA. In addition, it is important to avoid the restricted thinking of hypopharyngeal surgery as a singular event.

Age

In considering surgery for OSA, patients of extreme ages such as the elderly and infancy present as a management dilemma. It is increasingly important to deliberate over the issues surrounding the treatment of OSA in the elderly given the increase of aging population over 65 years all over the world. In a multicenter RCT performed on OSA patients aged older than 65 years, although CPAP was shown to provide better health outcomes and cost-effectiveness, compliance with CPAP therapy was suboptimal.⁵⁰ Although this makes a case for surgical intervention in this population, many patients have comorbidities that can preclude surgery. Furthermore, efficacy and potential risks of OSA surgery in this population group are still unclear given the lack of studies.

With younger children, timing and level of aggressiveness of intervention are debatable. This is especially resounding with the publication of evidence demonstrating that nasal resistance can lead to altered dentofacial morphology,⁵¹ which can predispose to OSA. It has also been shown that shortened lingual frenulum in young children can modify tongue position and affect orofacial growth, which can increase upper airway collapsibility during sleep.⁵²

This suggests early intervention on nasal breathing, correction of maxillary constriction and lingual frenectomy can potentially thwart the development in OSA further in life. In this aspect, orthodontic treatment such as maxillary expansion, nasal surgery, and lingual frenulectomy may complement traditional adenotonsillectomy. The counterargument for early intervention includes that of potential morbidity from surgery and disruption of cartilaginous growth centers pertaining to nasal or septal surgery.

OSA Severity

Traditionally, severe OSA predicts poorer response to surgery.⁵³ Hence, most contend that surgery should be avoided for this group of patients, or that only minimally invasive surgery should be done to facilitate CPAP usage. However, in the subgroup of patients with severe OSA who are unable to tolerate CPAP, one might argue for more aggressive surgical treatment to reduce upper airway obstruction and disease load. This is supported by the advent of new treatment modalities such as hypoglossal nerve stimulation which show promising treatment even for patients with severe OSA.⁴⁹ Moreover, with the increased understanding of OSA, it is now apparent that multilevel targeted surgery can improve surgical success.⁸ This opens up new possibilities and suggests the need for new paradigms in the surgical management of this group of patients with severe OSA.

Patient Preferences

The decision of treatment should take into account patient's preferences. The potential surgical morbidities, short and long-term benefits and treatment goal should be communicated to the patient, to aid decision-making. Taking into account the patient's views is fundamental to ensuring optimal patient involvement, treatment adherence, and superior treatment outcomes. This also

allows treatment to be tailored to individual clinical characteristics, taking into account each patient's variation in procedure and risk acceptability.

Postsurgery Positional OSA

In the postsurgical state, clinicians need to be aware that patients can have residual positional obstructive sleep apnea. As part of holistic management of OSA, clinicians should not be constrained one treatment methodology alone. Combined therapeutic strategy of surgery with positional therapy has been shown to improve AHI and Epworth Sleepiness Score in this group of patients.⁵⁴

Hypopharyngeal Surgeries at a Different Timeline

It is important to avoid the restricted thinking of hypopharyngeal surgeries for OSA as a singular event. Patients with concomitant pathologies such as those with large lingual tonsils and retrognathia/micrognathia may benefit from additional procedures such as genioplasty or MMA following lingual tonsillectomy, as a staged procedure. Likewise, patients who have subsequent failure following MMA may be suited and potentially benefit from hypoglossal nerve stimulation.⁵⁵ Hence it is important for the sleep surgeons to have the entire armamentarium of surgical capabilities and understand when to use them, to improve patient outcomes.

CONCLUSION

In this age of personalized and precision medicine, there is a gradual departure from the previous 'one size fits all' approach of single-level palatal reconstructive surgery for OSA treatment. In the context of hypopharyngeal surgery for OSA, the key to achieving an optimal outcome is the integration of targeted treatment, clinical expertise, and patient preference. Multilevel surgery and holistic management of OSA is likely to improve the overall outcomes.

CLINICAL SIGNIFICANCE

Hypopharyngeal obstruction is prevalent, and its presence is associated with increased OSA severity. Failure to address hypopharyngeal obstruction can lead to residual OSA and suboptimal treatment outcomes. Hence, it is important for sleep surgeons to complete their armamentarium with the ability to evaluate and provide corrective treatment for hypopharyngeal obstruction.

REFERENCES

- Fujita S, Conway W, et al. Surgical correction of anatomic abnormalities of obstructive sleep apnea syndrome: uvulopalatopharyngoplasty. *Otolaryngol Head Neck Surg.* 1981;89:923–934.
- Riley RW, Powell NB, et al. Obstructive sleep apnea syndrome: a surgical protocol for dynamic upper airway reconstruction. *J Oral Maxillofac Surg.* 1993;51(7):742–747.
- Vroegop VA, Vanderveken OM, et al. Drug-induced sleep endoscopy in sleep-disordered breathing: report on 1,249 cases. *Laryngoscope.* 2014;124(3):797–802.
- Phua CQ, Yeo WX, et al. Multi-level obstruction in obstructive sleep apnoea: prevalence, severity and predictive factors. *J Laryngol Otol.* 2017;131(11):982–986.
- Sher AE, Schechtman KB, et al. The efficacy of surgical modifications of the upper airway in adults with obstructive sleep apnea syndrome. *Sleep.* 1996;19(2):156–177.
- KK Li. Hypopharyngeal airway surgery. *Otolaryngol Clin N Am.* 2007;40:845–853.
- Kezirian EK, Goldberg AN. Hypopharyngeal surgery in obstructive sleep apnea: An evidence-based medicine review. *Arch Otolaryngol Head Neck Surg.* 2006;132:206–213.
- Lin HC, Friedman M, et al. The efficacy of multilevel surgery of the upper airway in adults with obstructive sleep apnea/hypopnea syndrome. *Laryngoscope.* 2008;118(5):902–908.
- Guimaraes KC, Drager LF, et al. Effects of oropharyngeal exercises on patients with moderate obstructive sleep apnea syndrome. *Am J Respir Crit Care Med.* 2009;179:962–966.
- Camacho M, Certal V, et al. Myofunctional Therapy to Treat Obstructive Sleep Apnea: A Systematic Review and Meta-analysis. *Sleep.* 2015;38(5):669–675.
- Li Y, Lin N, et al. Upper airway fat tissue distribution in subjects with obstructive sleep apnea and its effect on retropalatal mechanical loads. *Respir Care.* 2012;57(7):1098–1105.
- Kim AM, Keenan BT, et al. Tongue Fat and its Relationship to Obstructive Sleep Apnea. *Sleep.* 2014;37(10):1639–1648.
- Peppard PE, Young T, et al. Longitudinal study of moderate weight change and sleep-disordered breathing. *JAMA.* 2000;284(23):3015–3021.
- Subramani Y, Singh M, et al. Understanding Phenotypes of Obstructive Sleep Apnea: Applications in Anesthesia, Surgery, and Perioperative Medicine. *Anesth Analg.* 2017;124(1):179–191.
- Blumen M, Bequignon E, et al. Drug-induced sleep endoscopy: A new gold standard for evaluating OSAS? Part I: Technique. *Eur Arch Otorhinolaryngol Head Neck Dis.* 2017;134(2):101–107.
- De Vito A, Carrasco Llatas M, et al. European position paper on drug-induced sedation endoscopy (DISE). *Sleep and Breathing.* 2014;18(3):453–465.
- Kezirian EJ, Hohenhorst W, et al. Drug-induced sleep endoscopy: the VOTE classification. *Eur Arch Otorhinolaryngol.* 2011;268:1233–1236.
- Vicini C, De Vito A, et al. The nose oropharynx hypopharynx and larynx (NOHL) classification: a new system of diagnostic standardized examination for OSAS patients. *Eur Arch Otorhinolaryngol.* 2012;269:1297–1300.
- Certal VF, Pratas R, et al. Awake examination versus DISE for surgical decision making in patients with OSA: A systematic review. *Laryngoscope.* 2016;126(3):768–774.
- Huntley C, Chou D, et al. Preoperative Drug Induced Sleep Endoscopy Improves the Surgical Approach to Treatment of Obstructive Sleep Apnea. *Ann Otol Rhinol Laryngol.* 2017;126(6):478–482.
- Friedman M, Ibrahim H, et al. Clinical staging for sleep-disordered breathing. *Otolaryngol Head Neck Surg.* 2002;127:13–21.
- Harvey R, O'Brien L, et al. Friedman tongue position and cone beam computed tomography in patients with obstructive sleep apnea. *Laryngoscope Investig Otolaryngol.* 2017;2(5):320–324.
- Friedman M, Salapatas AM, et al. Updated Friedman Staging System for Obstructive Sleep Apnea. *Sleep-Related Breathing Disorders. Adv Otorhinolaryngol.* Basel, Karger. 2017;80:41–48.
- Friedman M, Yalamanchali S, et al. A Standardized Lingual Tonsil Grading System: Interexaminer Agreement. *Otolaryngology-Head and Neck Surgery.* 2014;151(1_suppl):47–48.
- Wee JH, Tan K, et al. Evaluation of coblation lingual tonsil removal technique for obstructive sleep apnea in Asians: preliminary results of surgical morbidity and prognosticators. *Eur Arch Otorhinolaryngol.* 2015;272(9):2327–2333.
- Leitzbach SU, Bodlaj R, et al. Safety of cold ablation (coblation) in the treatment of tonsillar hypertrophy of the tongue base. *Eur Arch Otorhinolaryngol.* 2014;271(6):1635–1639.
- Zhang Q, Zhou W, et al. Preliminary study on treatment of lingual tonsil hypertrophy by endoscopic assisted coblation. *Lin Chung Er Bi Yan Hou Tou Jing Wai Ke Za Zhi.* 2013;27(14):787–789.
- Rangabashyam M, Huang W, et al. State of the art transoral robotic surgery for obstructive sleep apnea-hypopnea syndrome. *Robotic Surgery: Research and Reviews.* 2016;3:13–28.
- Miller SC, Nguyen SA, et al. Transoral robotic base of tongue reduction for obstructive sleep apnea: A systematic review and meta-analysis. *Laryngoscope.* 2017;127(1):258–265.

30. Vicini C, Montevecchi F, et al. Clinical outcomes and complications associated with TORS for OSAHS: A benchmark for evaluating an emerging surgical technology in a targeted application for benign disease. *ORL*. 2014;76:63–69.
31. Torre C, Camacho M, et al. Epiglottis collapse in adult obstructive sleep apnea: A systematic review. *Laryngoscope*. 2016;126(2):515–523.
32. Catalfumo FJ, Golz A, et al. The epiglottis and obstructive sleep apnoea syndrome. *J Laryngol Otol*. 1998;112:940–943.
33. Toh ST, Han HJ, et al. Transoral robotic surgery for obstructive sleep apnea in Asian patients: a Singapore sleep centre experience. *JAMA Otolaryngol Head Neck Surg*. 2014;140:624–629.
34. Song SA, Chang ET, et al. Genial Tubercle Advancement and Genioplasty for Obstructive Sleep Apnea: A Systematic Review and Meta-Analysis. *Laryngoscope*. 2017;127:984–992.
35. Mackay SG, Carney AS, et al. Modified Uvulopalato-pharyngoplasty and Coblation Channeling of the Tongue for Obstructive Sleep Apnea: A Multi-Centre Australian Trial. *J Clin Sleep Med*. 2013;9(2):117–124.
36. Woodson BT, Steward DL, et al. A randomized trial of temperature-controlled radiofrequency, continuous positive airway pressure, and placebo for obstructive sleep apnea syndrome. *Otolaryngol Head Neck Surg*. 2003;128:848–861.
37. Steward DL, Weaver EM, et al. Multilevel temperature-controlled radiofrequency for obstructive sleep apnea: extended follow-up. *Otolaryngol Head Neck Surg*. 2005;132(4):630–635.
38. Zaghi S, Holty JE, et al. Maxillomandibular Advancement for Treatment of Obstructive Sleep Apnea: A Meta-analysis. *JAMA Otolaryngol Head Neck Surg*. 2016;142(1):58–66.
39. Riley RW, Powell NB, et al. Obstructive sleep apnea and the hyoid: a revised surgical procedure. *Otolaryngol Head Neck Surg*. 1994;111:717–721.
40. Stuck BA, Neff W, et al. Anatomic changes after hyoid suspension for obstructive sleep apnea: an MRI study. *Otolaryngol Head Neck Surg*. 2005;133(3):397–402.
41. Baisch A, Maurer JT, et al. The effect of hyoid suspension in a multilevel surgery concept for obstructive sleep apnea. *Otolaryngol Head Neck Surg*. 2006;134:856–861.
42. Verse T, Baisch A, et al. Multilevel surgery for obstructive sleep apnea: short-term results. *Otolaryngol Head Neck Surg*. 2006;134:571–577.
43. Ha JG, Min HJ, et al. The Dimension of Hyoid Bone Is Independently Associated with the Severity of Obstructive Sleep Apnea. *PLoS ONE*. 2013;8(12):e81590.
44. Hamans E, Stuck BA, et al. Hyoid expansion as a treatment for obstructive sleep apnea: a pilot study. *Sleep Breath*. 2013;17(1):195–201.
45. Toh ST, Hsu PP, et al. Hyoid Expansion With Titanium Plate and Screw A Human Cadaveric Study Using Computer-Assisted Airway Measurement. *JAMA Otolaryngol Head Neck Surg*. 2013;139(8):817–821.
46. Heiser C, Edenharter G, et al. Palatoglossus coupling in selective upper airway stimulation. *Laryngoscope*. 2017;127(10):E378–E383.
47. Strollo PJ Jr, Soose RJ, et al. Upper-airway stimulation for obstructive sleep apnea. *N Engl J Med*. 2014;370:139–149.
48. Woodson BT, Soose RJ, et al. Three-Year Outcomes of Cranial Nerve Stimulation for Obstructive Sleep Apnea: The STAR Trial. *Otolaryngol Head Neck Surg*. 2016;154(1):181–188.
49. Gillespie MB, Soose RJ, et al. Upper airway stimulation for obstructive sleep apnea: Patient reported outcomes after 48 months of follow-up. *Otolaryngology - Head and Neck Surgery*. 2017;156(4):765–771.
50. McMillan A, Bratton DJ, et al. Continuous positive airway pressure in older people with obstructive sleep apnoea syndrome (PREDICT): a 12 month multicenter randomized trial. *Lancet Respir Med*. 2014;2:804–812.
51. Harvold EP, Tomer BS, et al. Primate experiments on oral respiration. *Am. J. Orthod*. 1981;79:359–372. doi: 10.1016/0002-9416(81)90379-1.
52. Guilleminault C, Huseni S, et al. A frequent phenotype for paediatric sleep apnoea: short lingual frenulum. *ERJ Open Res*. 2016;2(3):00043–2016.
53. Caples SM, Rowley JA, et al. Surgical Modifications of the Upper Airway for Obstructive Sleep Apnea in Adults: A Systematic Review and Meta-Analysis. *Sleep*. 2010;33(10):1396–1407.
54. Benoist LBL, Verhagen M, et al. Positional therapy in patients with residual positional obstructive sleep apnea after upper airway surgery. *Sleep Breath*. 2017;21(2):279–288.
55. Ishman SL, Ishii LE, et al. Temporal trends in sleep apnea surgery: 1993–2010. *Laryngoscope*. 2014;124(5):1251–1258.