

CASE SERIES

Polyp within the Center of a Vocal Fold Sulcus: A Proposed Pathophysiologic Construct

¹Niv Mor, ²Juan C Hernandez-Prera, ³Christopher Tang, ⁴Andrew Blitzer

ABSTRACT

Objective: We noted unusual cases of vocal fold polyps originating from the center of vocal sulci and propose a possible etiology for the development of these lesions.

Materials and methods: Three patients presented to our office with acute onset dysphonia. Intraoperative examination revealed vocal polyps originating from the center of vocal sulci. Lesions were treated with microflap excisions and were sent for histopathologic analysis.

Results: Pathology of the excised lesions showed a parakeratotic squamous epithelium with mild inflammation and with dilated vascularity suggesting an acute or subacute process. Patients had voice improvement without recurrence of the vocal-polyp or sulcus following surgical excision.

Conclusion: We speculate that the observed lesions result from phonotrauma to congenital sulci and propose that partial prolapse of the epithelium is responsible for the formation of the observed vocal polyps.

Keywords: Polyp, Sulcus vergeture, Sulcus vocalis, Vocal fold.

How to cite this article: Mor N, Hernandez-Prera JC, Tang C, Blitzer A. Polyp within the Center of a Vocal Fold Sulcus: A Proposed Pathophysiologic Construct. *Int J Head Neck Surg* 2016;7(1):47-50.

Source of support: Nil

Conflict of interest: None

INTRODUCTION

Small alterations in the configuration of the mucosal vocal folds may have a large impact on laryngeal function

and voice. The clinical presentation of mucosal vocal fold lesions varies widely and many are only first noted under high power microscopic magnification in the operating room.¹⁻³ Although it is well accepted that some mucosal lesions are congenital and others are acquired, it is often challenging to know the true etiology of mucosal lesions.⁴⁻⁶ We noted three unusual cases of a vocal fold polyp originating from the center of a vocal fold sulcus and propose a possible etiology for the development of this lesion.

MATERIALS AND METHODS

Three patients presented to our office with complaint of acute onset dysphonia. An exophytic mucosal lesion originating from the center of a vocal sulcus was noted on intraoperative examination (Fig. 1). Patients were treated with microflap elevation and excision of the vocal fold lesion and sulcus. The tissue was sent for histopathologic analysis.

RESULTS

Patient demographics included two Hispanic females and one Caucasian male. Ages at presentation were 25, 44 and 51 years. One patient was a professional voice user and the other two were described by their family as excessively talkative. All patients had voice improvement following surgery. Physiologic mucosal wave formation had returned over subsequent follow-up visits. Histological evaluation of the vocal fold specimens showed a fibrinous and hemorrhagic stroma with dilated vascularity covered by a parakeratotic squamous epithelium with acute inflammation suggesting an acute or subacute process (Figs 2A to D).

DISCUSSION

We noted three patients with exophytic mucosal lesions originating from the center of a vocal sulcus. Patients' history and pathology suggest an acute or subacute process. Although the exact etiology of developing a polyp within a vocal sulcus is unknown, we propose that this lesion results from acquired stress on a congenital sulcus. In 1983 Bouchayer proposed that vocal fold sulcus, cysts and bridges are not independent entities and that the three lesions originate from a single process that incorporates both acquired and congenital processes.^{5,7} He considered

¹Physician, Assistant Clinical Professor

²Pathologist, Assistant Professor

³Physician/Laryngologist, ⁴Director, Adjunct Professor

¹Division of Otolaryngology-Head and Neck Surgery, Maimonides Medical Center, Voice and Swallowing Disorders; Downstate Medical Center, Brooklyn, New York, USA

²Mount Sinai Beth Israel Mount Sinai Health System; Department of Pathology, Icahn School of Medicine at Mount Sinai, New York, USA

³Department of Otolaryngology-Head and Neck Surgery, Kaiser Permanente Medical Center, San Francisco, CA, USA

⁴New York Center for Voice and Swallowing Disorders; Department of Neurology, Icahn School of Medicine at Mount Sinai New York, USA

Corresponding Author: Niv Mor, Physician, Assistant Clinical Professor, Division of Otolaryngology-Head and Neck Surgery, Maimonides Medical Center, 919 49th Street, Voice and Swallowing Disorders; Downstate Medical Center, Brooklyn, New York, USA, Phone: 9175028294, e-mail: nivmor73@gmail.com

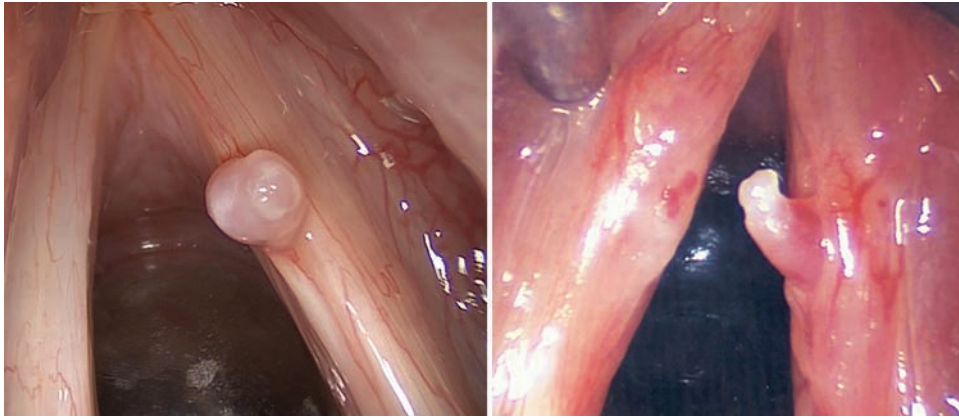
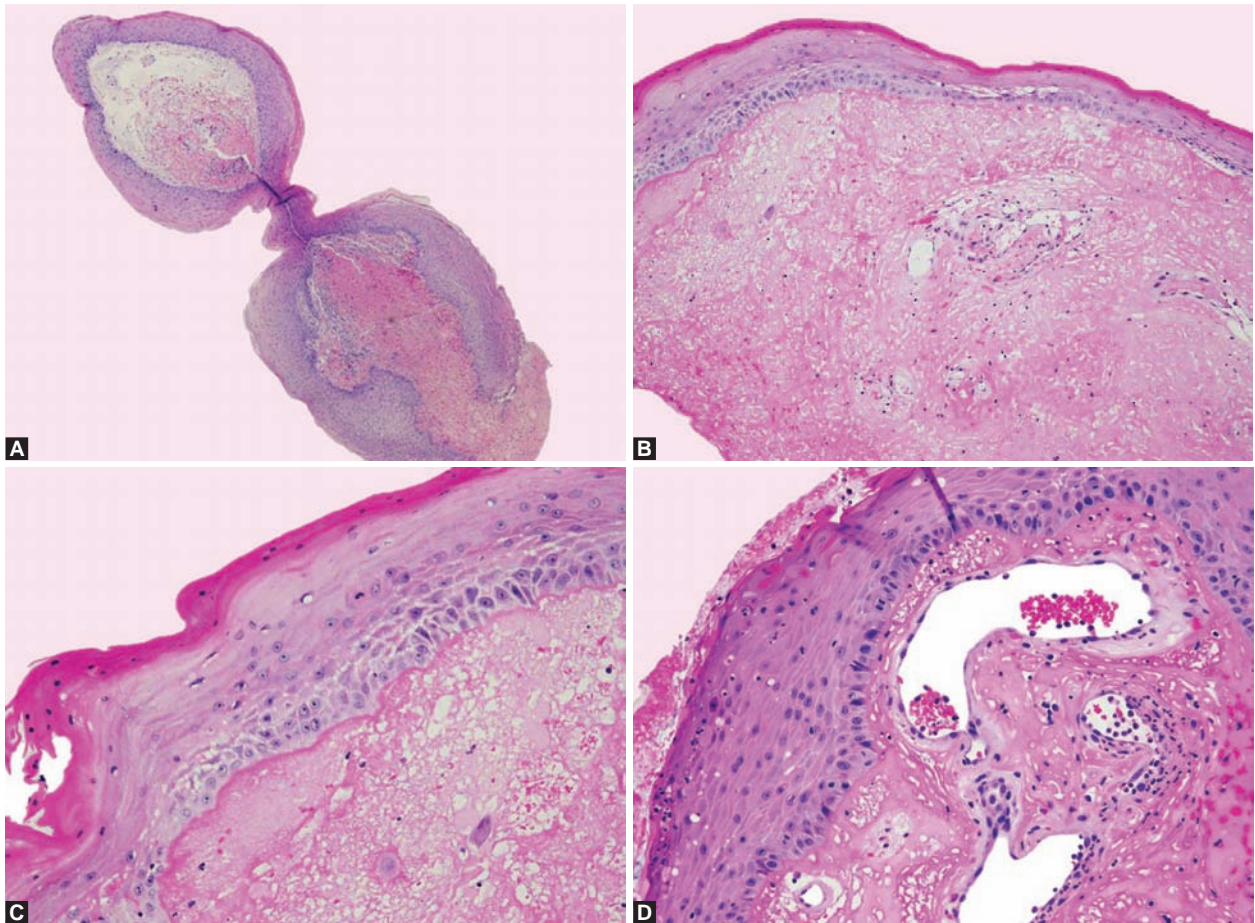


Fig. 1: Intraoperative images of polypoid lesion originated from the center of a vocal sulcus. Note contact lesion to left vocal fold on image to the right



Figs 2A to D: (A) Polypoid squamous epithelium from the center of sulcus vocalis; (B) subepithelial stroma with eosinophilic fibrinous material and edema; (C) squamous epithelium with parakeratosis and intracellular edema; and (D) acute inflammation and dilated subepithelial vascular spaces

epidermoid cysts to be congenital in origin and that a vocal fold sulcus forms following phonotrauma with subsequent cystic rupture. Like Bouchayer, we believe that the lesions seen in our patients result from excessive stress on pre-existing lesions; however, we propose that the vocal fold sulcus was pre-existing.

Mucosal vocal fold vibrations impose marked mechanical stress on the epithelium with maximal shear forces generated within the superficial lamina propria.⁸⁻¹³ As

the epithelium reaches its maximum position, the mucosal epithelium abruptly decelerates and reverses directions, generating a whiplash-like effect on the epithelium.^{8,13} Repeated phonotrauma on pre-existing sulcus could result in focal weakness to its attachment at the lamina propria. Furthermore, pre-existing structural lesions alter normal mucosal wave aerodynamics leading to greater impact to the epithelium. Recurrent phonotrauma could result in focal weakness and separation of sulcus




Fig. 3: Schematic representation of phonotrauma on pre-existing sulcus showing focal weakness and separation of sulcus attachment at the lamina propria resulting in partial prolapse of the epithelium and subsequent polypoid lesion within the center of a vocal sulcus

attachment at the lamina propria resulting in partial prolapse of the epithelium and subsequent polypoid lesion within the center of a vocal sulcus (Figs 1 and 3).

While the sulcus in the above patients could have also developed from a ruptured cyst, it is also plausible that the observed sulci were congenital in origin. In 1996 Ford classified sulci into three subtypes.^{14,15} A type I sulcus is physiologic. It does not adhere to the underlying lamina propria and is usually incidentally noted. By contrast, a type III sulcus, sulcus vocalis, is characterized by a pit shaped sulcus at the medial edge of the vocal fold and generally tracts laterally. The epithelium in a type III sulcus is strongly adherent to the deeper layers of the lamina propria. These mucosal lesions are commonly symptomatic and associated with varying degrees of inflammation. Bouchayer's theory regarding the etiology of a sulcus vocalis, generally refers to a type III lesion.^{7,14,16} By contrast, a type II sulcus, sulcus vergeture, is far less adherent to the lamina propria. It has a thin overlying mucosal epithelium and demonstrates only focal loss at the underlying superficial lamina propria. Despite the apparent similarities of type II sulcus and a type III sulcus, the two are thought of as independent entities. Numerous studies have noted type II lesions within the same family members and they are commonly believed to be hereditary in origin.¹⁷⁻²¹

Further evidence of congenital sulci was noted in excised neonatal larynges.²² Silva et al examined 56 larynges for evidence of congenital anomalies. Five of six observed abnormalities were microdiaphragms and one was a vocal fold sulcus. Although we cannot discount that further mucosal alterations may present later in development, it is interesting to note that they did not note the presence of any congenital vocal cysts. Findings by Sato and Hirano also suggest that sulci result from developmental anomalies.²³ They examined the vocal fold epithelium by electron microscopy and noted alterations to the macula flavae in vocal folds containing sulci. The maculae flavae is instrumental in vocal fold growth, development and aging, and alterations to the macula flavae resulted in abnormal production of collagen and elastic fibers within the vocal fold epithelium. These observations are unlikely to result from external stimuli alone.²⁴

Other studies have also noted associations between the presence of vocal fold polyps and pre-existing mucosal alterations.^{25,26} Eckley et al reported that 51% of their patients with polyps had some pre-existing vocal fold alteration and sulci were the most commonly found lesions.^{27,28} Another study of 280 patients with vocal fold polyps found a 6.4% prevalence of a concurrent vocal fold sulcus.²⁹

It is thus possible that observed lesions resulted from acute phonotrauma to pre-existing type II congenital sulcus. Nevertheless, our theoretical construct has numerous limitations. We suggest an explanation to an observed phenomenon and are limited by our ability to use objective data to prove this theory. As such, the observed lesions could have just as well developed from trauma alone. It is also possible that a phonotraumatic polyp exerted repeated stress to the underlying lamina propria causing scar and subsequent development of a vocal fold sulcus. We must also acknowledge that our numbers are extremely low and reflect an observation seen only in three patients. By contrast, Bouchayer's work was founded on observations of 157 patients and pathologic specimens which informed his proposed hypothesis. Further investigations are thus needed to elucidate the exact etiology of these observed vocal lesions.

CONCLUSION

Although the pathophysiology of the observed lesions is unknown, we speculate that they originate from a process that incorporates both acquired and congenital theories. We propose that repeated phonotrauma to a pre-existing vocal sulcus predispose patients to develop a vocal fold polyp within the center of this lesion and suggest that the preexisting lesion is a type II congenital sulcus.

REFERENCES

1. Gull J, Divi J, Ghaderi M, Sataloff RT. Bilateral occult mucosal bridges of the true vocal folds. *J Voice* 2009 Nov;23(6):733-734.
2. Hirano M, Tanaka S, Tetsuji Y, Hibi S. Sulcus vocalis: functional aspects. *Ann Otol Rhinol Laryngol* 1990;99(9):679-683.
3. Hirano M. Phonosurgical anatomy of the larynx. In: Ford CN, Bless DM, editors. *Phonosurgery: assessment and surgical management of voice disorders*. Raven Press, New York (1991). pp. 25-41.

4. Monday LA, Bouchayer M, Cornut G, Roch JB. Epidermoid cysts of the vocal cords. *Ann Otol Rhinol Laryngol* 1983;92(2):124-127.
5. Bouchayer M, Cornut G, Witzig E, Loire R, Roch JB, Bastian RW. Epidermoid cysts, sulci, and mucosal bridges of the true vocal cord: a report of 157 cases. *Laryngoscope* 1985 Sep;95(9):1087-1094.
6. Giovanni A, Chanteret C, Lagier A. Sulcus vocalis: a review. *Eur Arch Otorhinolaryngol* 2007;264(4):337-344.
7. Bouchayer M, Cornut G. Microsurgical treatment of benign vocal fold lesions: indications, technique, results. *Folia Phoniatr* 1992;44(3-4):155-184.
8. Sonninen A, Laukkanen A. Hypothesis of whiplike motion as a possible traumatizing mechanism in vocal fold vibration. *Folia Phoniatr Logop* 2003;55(4):189-198.
9. Berry DA, Montequin D, Tayama N. High-speed digital imaging of the medial surface of the vocal folds. *J Acoust Soc Am* 2001;110(5):2539-2547.
10. Colton RH. Physiological mechanisms of vocal frequency control: the role of tension. *J Voice* 1988;2(3):208-220.
11. Sonninen A, Damsté PH, Jol J, Fokkens J. On vocal strain. *Folia Phoniatr* 1972;24(5-6):336.
12. Titze, Ingo R. Principles of voice production. Englewood Cliffs N.J., Prentice-Hall, 1994. p. 94-95.
13. Hochman I, Hillman RE, Sataloff RT, Zeitels SM. Ectasias and varices of the vocal fold: clearing the striking zone. *Ann Otol Rhinol Laryngol* 1999;108(1):10-16.
14. Ford CN, Inagi K, Khidr A, Bless DM, Gilchrist KW. Sulcus vocalis: a rational approach to diagnosis and management. *Ann Otol Rhinol Laryngol* 1996;105(3):189-200.
15. Ford CN. Advances and refinements in phonosurgery. *Laryngoscope* 1999;109(12):1891-1900.
16. Friedrich G, Dikkers FG, Arens C, et al. Vocal fold scars: current concepts and future directions. Consensus report of the phonosurgery committee of the European laryngological society. *Eur Arch Otorhinolaryngol* 2013 Sep;270(9):2491-2507.
17. Husain S, Sulica L. Familial sulcus vergeture: further evidence for congenital origin of type 2 sulcus. *J Voice* 2015; In press.
18. Trevin J, Chessebeuf L, Cornut G. A propos de 3 cas familiaux de sulcus glottidis. *Bull d'Audiophonol* 1977;7:75-81.
19. Martins RH, Silva R, Ferreira DM, et al. Sulcus vocalis: probable genetic etiology. Report of four cases in close relatives. *Braz J Otorhinolaryngol* 2007;73(4):573.
20. Cakir ZA, Yigit O, Kocak I, et al. Sulcus vocalis in monozygotic twins. *Auris Nasus Larynx* 2010;37(2):255-257.
21. Martins RH, Goncalves TM, Neves DS, et al. Sulcus vocalis: evidence for autosomal dominant inheritance. *Genet Mol Res* 2011;10(4):3163-3168.
22. Silva AR, Machado AJ Jr, Crespo AN. Anatomical study of minor alterations in neonate vocal folds. *Braz J Otorhinolaryngol* 2014;80(4):311-317.
23. Sato K, Hirano M. Electron microscope investigation of sulcus vocalis. *Ann Otol Rhinol Laryngol* 1998 Jan;107(1):56-60.
24. Hirano M. Phonosurgery; basic and clinical investigations *Otologia*. Fukuoka 1975;21:239-442.
25. Sataloff RT, Hawkshaw MJ, Nagorsky M. Vocal fold polyp, scar, and sulcus vocalis. *Ear Nose Throat J* 2000;79(10):768.
26. Tan M, Pitman MJ. A case of bilateral vocal fold mucosal bridges, bilateral transvocal fold type III sulci vocales, and an intracordal polyp. *J Voice* 2011;25(4):484-486.
27. Eckley CA, Swensson J, Duprat AC, Donati F, Costa HO. Incidence of structural vocal fold abnormalities associated with vocal fold polyps. *Braz J Otorhinolaryngol* 2008;74(4):508-511.
28. Eckley CA, Corvo MA, Yoshimi R, Swensson J, Duprat AC. Unsuspected intraoperative finding of structural abnormalities associated with vocal fold polyps. *J Voice* 2010;24(5):623-625.
29. Byeon HK, Kim JH, Kwon JH, Jo KH, Hong HJ, Choi HS. Clinical characteristics of vocal polyps with underlying sulcus vocalis. *J Voice* 2013;27(5):632-635.